

# Multiple Structural Failures of Aortic Homografts Leading to Emergency Surgery

Tomislav Tokić<sup>1</sup>, Nora Knez<sup>2</sup>, Ante Lekić<sup>1</sup>, Mario Pavlek<sup>3</sup>, Lara Lalić Tokić<sup>3</sup>, Maja Hrabak Paar<sup>4</sup>, Hrvoje Gašparović<sup>1</sup>

<sup>1</sup> Department of Cardiac Surgery, University Hospital Center Zagreb, Zagreb, Croatia

<sup>2</sup> School of Medicine, University of Zagreb, Zagreb, Croatia

<sup>3</sup> Department of Anesthesiology, University Hospital Center Zagreb, Zagreb, Croatia

<sup>4</sup> Department of Radiology, University Hospital Center Zagreb, Zagreb, Croatia

OPEN ACCESS

## Correspondence:

Hrvoje Gašparović  
hgasparovic@gmail.com

This article was submitted to RAD  
CASA - Medical Sciences  
as the original article

## Conflict of Interest Statement:

The authors declare that the research was conducted in the absence of any commercial or financial relationships that could be construed as a potential conflict of interest.

**Received:** 20 September 2022

**Accepted:** 13 December 2022

**Published:** 21 December 2022

## Citation:

Tokić T, Knez N, Lekić A, Pavlek M, Lalić Tokić L, Hrabak Paar M, Gašparović H. Multiple Structural Failures of Aortic Homografts Leading to Emergency Surgery RAD CASA - Medical Sciences. 553=60-61 (2022): 116-119 DOI: 10.21857/y6z0lb625m

Copyright (C) 2022 Tokić T, Knez N, Lekić A, Pavlek M, Lalić Tokić L, Hrabak Paar M, Gašparović H. This is an open-access article distributed under the terms of the Creative Commons Attribution License (CC BY). The use, distribution or reproduction in other forums is permitted, provided the original author(s) and the copyright owner(s) are credited and that the original publication in this journal is cited, in accordance with accepted academic practice. No use, distribution or reproduction is permitted which does not comply with these terms.

## ABSTRACT

Aortic homografts are composed of aortic roots and variable lengths of the arch and ascending aorta, harvested from donor hearts. They are primarily used in extensive aortic root endocarditis due to its resistance to reinfection. They are, however, prone to structural failure. Redo aortic root surgery is challenging, especially in the setting of aneurysms or pseudoaneurysms (PSAN) lying immediately posterior to the sternum or adhering to it. We present a 43-year-old female with two aortic homograft pseudoaneurysms following her fourth aortic valve and ascending aortic procedure. The first PSAN was described as immediately cranial to proximal homograft anastomosis, measuring 21x8 millimeters. It harbored potential for intraoperative rupture because of its proximity to the posterior sternal table. The second one was 36x20 millimeters, adjacent to the distal homograft anastomosis. The surgical plan entailed institution of peripheral hypothermic cardiopulmonary bypass due to an almost inevitable risk of bleeding from the retrosternal pseudoaneurysm. While the actual sternotomy was uneventful, the PSAN ruptured after sternal retraction. The ensuing massive bleeding was expected and was successfully managed during hypothermic circulatory arrest. The patient had an unremarkable postoperative course and was discharged home.

**KEYWORDS:** homograft, pseudoaneurysm, aortic surgery, cardiac surgery

## SAŽETAK

VIŠESTRUKA STRUKTURNA OŠTEĆENJA AORTALNIH HOMOGRAFTA U HITNOJ KARDIOKIRURŠKOJ OPERACIJI Aortalni homograft je segment kadaveričnog korijena aorte, uzlazne aorte te luka aorte različite duljine. Najčešće se uzima od eksplantiranog primaočevog srca prilikom transplantacije srca. Poglavitno se koristi u infektivnom endokarditisu zbog svoje rezistencije prema reinfekciji. Nažalost, sklon je strukturalnom propadanju. Kardiokirurške reoperacije korijena aorte i uzlazne aorte su kompleksne, pogotovo uz pseudoaneurizme ili aneurizme koje se nalaze neposredno retrosternalno. Prikazujemo slučaj 43-godišnje pacijentice koja se prezentirala s dvije pseudoaneurizme homografta uzlazne aorte, te je prethodno već imala četiri kardiokirurška zahvata. Prva pseudoaneurizma bila je veličine 21x8 milimetara, odmah retrosternalno, dok je druga bila neposredno pored distalne anastomoze homografta, veličine 36x20 milimetara. Operacijski plan uključivao je uspostavu hipotermijskog perifernog izvantjelesnog krvotoka prije sternotomije, radi visokog rizika od rupture pseudoaneurizme. Iako je sternotomija prošla bez komplikacija, neposredno nakon sternalne trakcije došlo je i do očekivane rupture pseudoaneurizme.

Navedeno je zahtijevalo rješavanje aortalne patologije u cirkulacijskom arestu. Nakon uspješno izvedenog zahvata, bolesnica je imala povoljan poslijeoperacijski tijek nakon kojeg je otpuštena kući.

**KLJUČNE RIJEČI:** homograft, pseudoaneurizma, kirurgija aorte, kardiokirurgija

## INTRODUCTION

Aortic homograft is an aortic valve, root, and ascending aortic allograft obtained from a donor heart or autopsy. Ever since Cooley used the homograft in a resection of the fusiform aneurysm of the ascending aorta in 1956 (1), aortic homografts have been widely used to treat aortic valve, aortic root, and/or ascending aorta pathology. Homograft use is particularly widespread in aortic valve endocarditis due to its noticeably low risk of reinfection (2). However, homografts are associated with severe aortic regurgitation up to 35% after 15 years (when being used for aortic valve pathology) and structural failure leading to 34% and 51% need explantation after 15 and 20 years, respectively. Young recipient age is a known factor for structural failure (3). Reoperative surgery of the aortic root and the ascending aorta is one of the most challenging procedures in adult cardiac surgery, especially in the setting of aneurysms or pseudoaneurysms (PSAN) lying immediately posterior to the posterior side of the sternum. It requires careful preoperative planning and an experienced surgical team. We present a case of a 43-year-old female with two aortic homograft pseudoaneurysms following her fourth aortic valve and ascending aortic procedure.

## CASE REPORT

We present a case of a 43-year-old female with aortic homograft PSANs. The patient underwent open commissurotomy when she was 13 for aortic stenosis. 7 years ago she was admitted to our institution due to severe aortic insufficiency and ascending aortic and arch aneurysm. She underwent surgical aortic valve replacement (SAVR) with a mechanical prosthesis, combined with ascending aorta and hemiarch resection and reconstruction in deep hypothermic circulatory arrest (DHCA) with antegrade cerebral perfusion. She developed acute bacterial endocarditis of the aortic valve and aortic graft secondary to an *Enterobacter* spp. ESBL infection. Due to the aforementioned reasons, she underwent a second redo procedure. After removal of all prosthetic material, thorough debridement of infected tissues was performed. The aortic valve was again replaced with a mechanical prosthesis, along with replacement of the ascending aorta and hemiarch with two homografts. Circulatory arrest was again employed for aortic arch surgery. After a favorable immediate postopera-

tive course, she acutely developed massive bleeding. Salvage sternotomy was done in the intensive care unit. The bleeding site was identified within the shaft of the homograft. Control of bleeding was technically challenging and required emergent CPB and DHCA. The homograft defect was reconstructed with a bovine pericardial patch and topical hemostatics. Remarkably, the patient recovered without sequelae and was discharged after completion of a prolonged course of intravenous antibiotics. The most recent hospitalization was prompted by a newly diagnosed pair of PSANs (Figure 1). The first one was located cranial to the proximal homograft anastomosis, measuring 21x8 mm. It was immediately retrosternal (Figure 2a). The second one was 36x20 mm, on the posterior side of the distal homograft anastomosis (Figure 2b). The ascending aortic homograft was also described as being immediately retrosternal. As the risk of injury to the homograft due to its proximity to the posterior sternal table was felt to be prohibitively high, we opted to start cardiopulmonary bypass (CPB) with moderate hypothermia via peripheral vessels prior to sternotomy. These maneuvers proved to be crucial, as profuse bleeding was encountered after a sternal retractor was placed. Lateral force exerted by the retractor exceeded the structural integrity of the pseudoaneurysm. The massive hemorrhage was initially contained with sternal compression and continuous pump sucker aspiration. DHCA was initiated after satisfactory superior vena cava oxygen saturation indicated low brain oxygen consumption. Nearly complete disintegration of the anterior wall of the homograft was verified. There was also a rupture of the aortic arch, consistent with the preoperative diagnosis of a PSAN. Anterograde brain perfusion was established. The entire homograft was resected and excluded from the circulation. During circulatory arrest the arch anastomosis with a Dacron graft was performed. The graft was then cross-clamped, and CPB was reinitiated. The remainder of the ascending aorta was replaced with the Dacron graft which was now sutured to the aortic root. The patient was weaned off CPB uneventfully, on minimal inotropic support. She was extubated 14 hours after admission to ICU. Her postoperative stay was uneventful, and she was discharged home on the 13th POD. Serial follow-up examinations confirmed a very favorable postoperative course. She has resumed normal daily activities to the fullest extent.

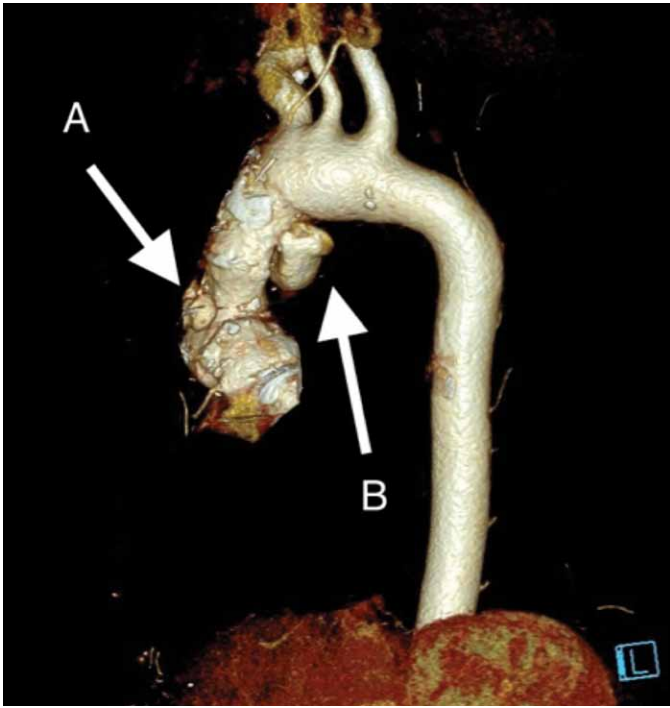


Figure 1. A multislice computed tomography reconstruction of aortography showing both pseudoaneurysms (A and B).

**DISCUSSION**

An aortic homograft was first used by Cooley in 1956 for the treatment of a fusiform aneurysm of the ascending aorta (1). Ross reported the first use of the homograft for aortic valve replacement in 1962 (4). Since then, homograft use has been widespread in the aortic valve, root, and ascending aortic surgery, especially in the milieu of infective endocarditis (5). Its benefit in this setting is related to its noticeably lower risk of reinfection (2). Unfortunately, homografts are prone to structural failure, (6). Recently, new developments were made to ensure better structural integrity of the homograft, including tissue cryopreservation (7). According to a study by Witten et al. (3), severe aortic regurgitation was present in 35% of the patients 15 years after homograft root replacement, with 34% and 51% of homografts

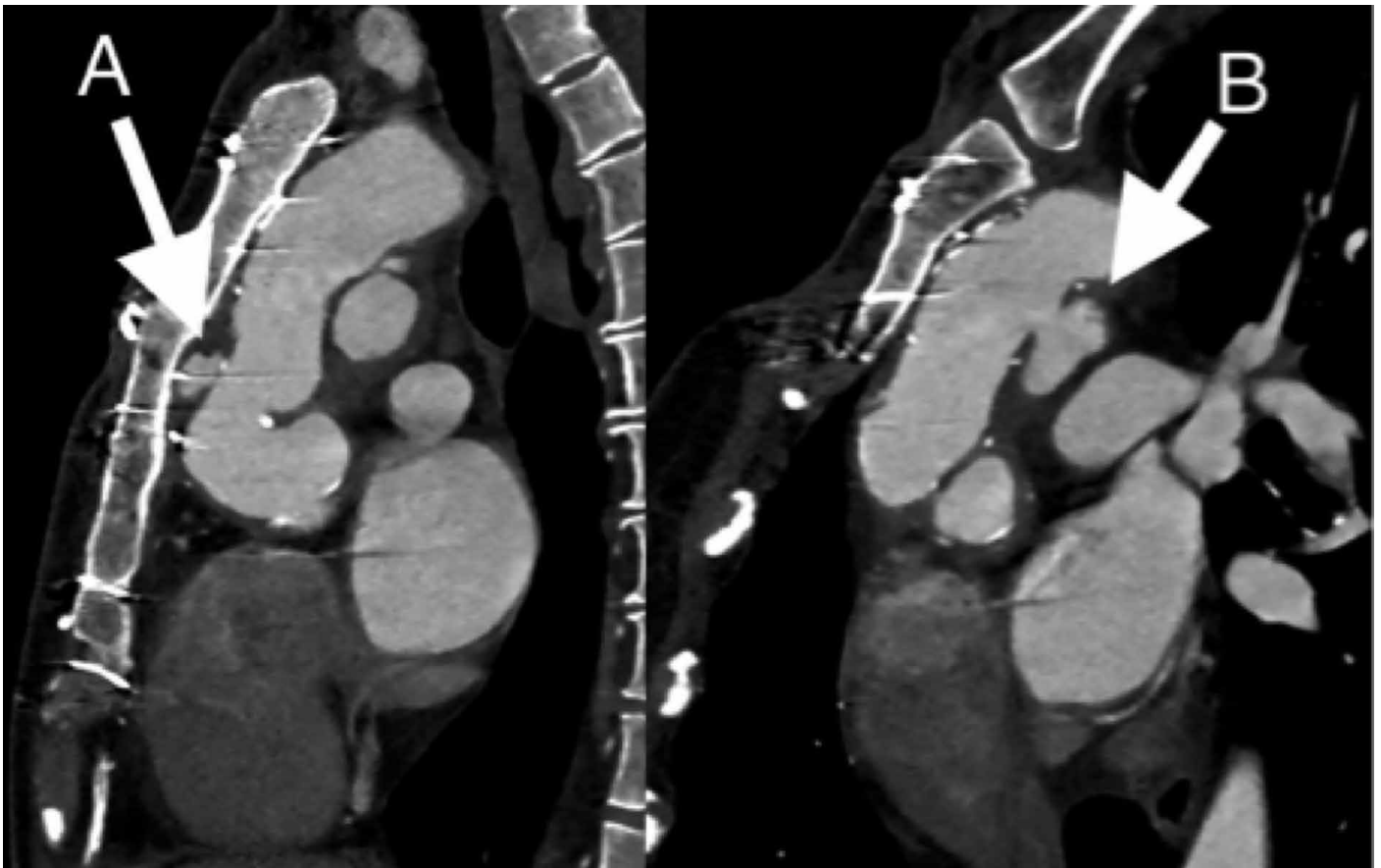


Figure 2. A sagittal computed tomography aortography. Figure 2a shows the proximal pseudoaneurysm (A) and its relation to the posterior side of the sternum. Note also the proximity of the homograft to the sternum. Figure 2b shows the distal pseudoaneurysm (B), along with its neck.

being explanted for structural failure after 15 and 20 years, respectively. Young recipient age is a known factor for structural failure. PSANs, or false aneurysms, are known and described in the context of homograft deterioration (8). A report of an imminent transcatheter rupture of an aortic homograft PSAN has been published (9). Reoperations for homograft failure are challenging, with an elevated risk of both morbidity and mortality. In our case, preoperative CT verified a PSAN immediately retrosternally, which necessitated peripheral cannulation and careful preoperative planning. Massive aortic hemorrhage upon sternotomy was controlled in line with preoperative planning. Upon DHCA initiation and finishing the sternotomy, nearly complete disintegration of the anterior wall of the homograft was verified, along with a rupture on the concave side of the aortic arch.

## CONCLUSION

Aortic homograft structural failure necessitates a high-risk and complex surgical procedure, especially when coupled with previous multiple aortic valve/ascending aorta procedures. Detailed preoperative imaging is mandatory to devise the best perioperative strategy for each patient. In our case, we have shown that complex homograft failures are surgically treatable with good results if done by an experienced surgical team and adequate preoperative planning.

## REFERENCES:

1. Cooley DA. Resection of Entire Ascending Aorta In Fusiform Aneurysm Using Cardiac Bypass. *J Am Med Assoc.* 1956;162:1158.
2. Solari S, Mastrobuoni S, de Kerchove L, Navarra E, Astarci P, Noirhomme P, et al. Over 20 years experience with aortic homograft in aortic valve replacement during acute infective endocarditis. *European Journal of Cardio-Thoracic Surgery.* 2016;50:1158–64.
3. Witten JC, Durbak E, Houghtaling PL, Unai S, Roselli EE, Bakaeen FG, et al. Performance and Durability of Cryopreserved Allograft Aortic Valve Replacements. *Ann Thorac Surg.* 2021;111:1893–900.
4. Ross DN. Homograft Replacement of The Aortic Valve. *The Lancet.* 1962;280:487.
5. Staab ME, Nishimura RA, Dearani JA, Orszulak TA. Aortic Valve Homografts in Adults: A Clinical Perspective. *Mayo Clin Proc.* 1998;73:231–8.
6. El-Hamamsy I, Clark L, Stevens LM, Sarang Z, Melina G, Takkenberg JJM, et al. Late Outcomes Following Freestyle Versus Homograft Aortic Root Replacement. *J Am Coll Cardiol.* 2010;55:368–76.
7. O'Brien MF, McGiffin DC, Stafford EG, Gardner MAH, Pohlner PF, McLachlan GJ, et al. Allograft Aortic Valve Replacement: Long-Term Comparative Clinical Analysis of the Viable Cryopreserved and Antibiotic 4°C Stored Valves. *J Card Surg.* 1991;6(4S):534–43.
8. Coutinho GF, Antunes MJ. Pseudoaneurysm of an Aortic Homograft. *Ann Thorac Surg.* 2006;82:2280–2.
9. Sandoval E, Schneider SR, Ruiz-Abad J, Pereda D. Immigrant transcatheter rupture of an aortic homograft pseudoaneurysm. *European Journal of Cardio-Thoracic Surgery.* 2020;57:610