

# Extracorporeal shock wave lithotripsy – a non-invasive treatment modality for urolithiasis in University Hospital Centre Zagreb

Tvrtko Hudolin<sup>1,2,\*</sup>, Toni Zekulić<sup>1,\*</sup>, Vedran Andrijašević<sup>1</sup>, Marjan Marić<sup>1</sup>, Milko Padovan<sup>1</sup>, Tomislav Kuliš<sup>1,2</sup>, Luka Penezić<sup>1</sup>, Jerko Anđelić<sup>1</sup>, Hrvoje Saić<sup>1</sup>, Tomislav Sambolić<sup>1</sup>, Marko Nakić<sup>3</sup>, Željko Kaštelan<sup>1,2,4</sup>

<sup>1</sup> University Hospital Centre Zagreb, Kišpatičeva ulica 12, 10000 Zagreb, Croatia

<sup>2</sup> University of Zagreb, School of Medicine, Šalata 3, 10000 Zagreb, Croatia

<sup>3</sup> General Hospital Šibenik, Ul. Stjepana Radića 83, 22000, Šibenik, Croatia

<sup>4</sup> Croatian academy of sciences and arts, Trg Nikole Zrinskog 11, 10000 Zagreb, Croatia

OPEN ACCESS

## Correspondence:

Tvrtko Hudolin  
tvrtkohudolin@gmail.com

This article was submitted to RAD  
CASA - Medical Sciences  
as the original article

## Conflict of Interest Statement:

The authors declare that the research was conducted in the absence of any commercial or financial relationships that could be construed as a potential conflict of interest.

Received: 27 November 2023

Accepted: 5 December 2023

Published: 22 December 2023

## Citation:

Hudolin T, Zekulić T, Andrijašević V, Marić M, Padovan M, Kuliš T, Penezić L, Anđelić J, Saić H, Sambolić T, Nakić M, Kaštelan Ž. Extracorporeal shock wave lithotripsy – a non-invasive treatment modality for urolithiasis in University Hospital Centre Zagreb 559=64-65 (2023): 64-68  
DOI: 10.21857/mjrl3ug719

Copyright (C) 2023 Hudolin T, Zekulić T, Andrijašević V, Marić M, Padovan M, Kuliš T, Penezić L, Anđelić J, Saić H, Sambolić T, Nakić M, Kaštelan Ž. This is an open-access article distributed under the terms of the Creative Commons Attribution License (CC BY). The use, distribution or reproduction in other forums is permitted, provided the original author(s) and the copyright owner(s) are credited and that the original publication in this journal is cited, in accordance with accepted academic practice. No use, distribution or reproduction is permitted which does not comply with these terms.

## ABSTRACT:

Urolithiasis is one of the most common pathologies in urology, with high prevalence and recurrence rates. Urinary tract stones differ in their symptomatology, number, size, location, structure, as well as in some other characteristics and thus in the way of their treatment. Computed tomography (CT) is considered the best method of diagnosing stones and choosing the optimal treatment method for patients with urinary tract stones. Extracorporeal shock-wave lithotripsy (ESWL) is an effective treatment modality in patients with stones less than 20 mm in size. Because of the characteristics of stones, in some cases, more than one procedure is needed to achieve complete disintegration. From January 2019 to November 2023, 3,844 EWSL treatments for urinary tract stones were performed at the Clinical Hospital Center Zagreb Urology Clinic. The average stone size was 0.9 cm, and the average age of the patients was 53 years. One ESWL treatment was needed in 22%, two in 21%, and three in 18% of our patients. The procedure could not be performed due to the radiolucency of stones on X-ray images in 10% of patients, while it was interrupted in 3% due to pain, and in 3% of patients due to hypertension.

In patients with unsuccessful extracorporeal treatments or an initially high burden of stones, some of the minimally-invasive, endoscopic methods are advised for further or initial treatment, such as ureteroscopy (URS), flexible ureterorenoscopy (FURS), percutaneous nephrolithotomy (PCNL), and endoscopic combined intrarenal surgery (ECIRS).

ESWL is considered an effective, non-invasive treatment modality in selected patients, with good stone-free rates and low complication rates, which can be performed as an outpatient procedure.

**KEYWORDS:** Extracorporeal shock-wave lithotripsy; ESWL; urolithiasis

## SAŽETAK:

EKSTRAKORPORALNA LITOTRIPSIIJA UDARNIM VALOM – NEINVAZIVNI NAČIN LIJEČENJA UROLITIJAZE U KBC-U ZAGREB

Urolitijaza je jedna od najčešćih patologija u urologiji, s visokom prevalencijom i stopom recidiva. Kamenci mokraćnog sustava razlikuju se po svojoj simptomatologiji, broju, veličini, smještaju, strukturi, ali i po nekim drugim karakteristikama pa tako i po načinu liječenja. Kompjuterizirana tomografija (CT) smatra se najboljom metodom dijagnostike kamenaca i odabira optimalne metode liječenja bolesnika s kamencima mokraćnog sustava. Ekstrakorporalna litotripsija udarnim valom (ESWL) je efikasan način liječenja bolesnika s kamencima manjim od 20 mm. U nekim je slučajevima, zbog

svojstava kamenaca potrebno više od jednog postupka, kako bi se postigla potpuna dezintegracija. Od siječnja 2019. do studenog 2023. u Klinici za urologiju KBC-a Zagreb obavljena su 3844 ESWL tretmana kamenaca mokraćnog sustava. Prosječna veličina kamenca je bila 0,9 cm, a prosječna dob pacijenata 53 godine. Jedan ESWL tretman bio je potreban u 22%, dva u 21%, a tri u 18% naših pacijenata. Zahvat se nije mogao izvesti zbog radiolucencije kamenaca na rendgenskim snimkama u 10% pacijenata, dok je u 3% prekinut zbog boli, a u 3% bolesnika zbog hipertenzije. U bolesnika s neuspješnim izvantjelesnim tretmanima ili inicijalno velikim kamencima mokraćnog sustava savjetuju se neke od minimalno invazivnih, endoskopskih metoda naknadnog, odnosno inicijalnog liječenja, kao što su ureteroskopija (URS), fleksibilna ureterorenoskopija (FURS), perkutana nefrolitotomija (PCNL) ili endoskopska kombinirana intrarenalna kirurgija (ECIRS). ESWL se smatra učinkovitim, neinvazivnim modalitetom liječenja u odabраниh pacijenata, s dobrim rezultatima i malom stopom komplikacija koji se može izvesti kao ambulantni postupak.

**KLJUČNE RIJEČI:** vanttjelesno mrvljenje kamenaca; ESWL; urolitijaza

## INTRODUCTION

Urolithiasis is one of the most common pathologies in urology, with high prevalence and recurrence rates. Although it is rarely a life-threatening disease, it is the cause of a large number of visits to the general practitioner, but also to the urologist, and to the emergency urology service in the hospital.

Kidney stones are a complex disease, and they can be divided into several subgroups. For example, depending on the cause, they can be divided into infectious, non-infectious and genetic. The composition of the stone is often mixed, consisting of various substances and mineral components, most often calcium, carbonate, phosphate, ammonia, sodium, and magnesium. Many patients with urolithiasis can be asymptomatic, but the most common clinical symptom is renal colic (1). It is often associated with nausea and vomiting, dysuria, and the presence of blood in the urine. After medical history and physical examination, ultrasound (US) should be used as the initial imaging modality of choice, primarily to check for hydronephrosis. It has a sensitivity of 45% for renal and ureteral stones, and specificity of 94% for ureteral, and 88% for renal stones (2). The plain X-ray of the kidney, ureter, and bladder has a sensitivity and specificity of 44-77%, but it is helpful in the differentiation of radiolucent stones and during follow-up (3). CT is the "gold standard" for urinary stones diagnosis, and it is mandatory for planning the right approach to urolithiasis treatment. It can determine stone density, shape, location, and size, as well as the surrounding anatomy and skin-to-stone distance (4). Immediate imaging is indicated in patients with fever and/or solitary kidney with hydronephrosis. A low-dose CT can be used to reduce radiation risk. A CT urography should be used if an anomaly or variation of urinary tract anatomy is suspected. The active treatment of kidney stones is indicated in patients with stones larger

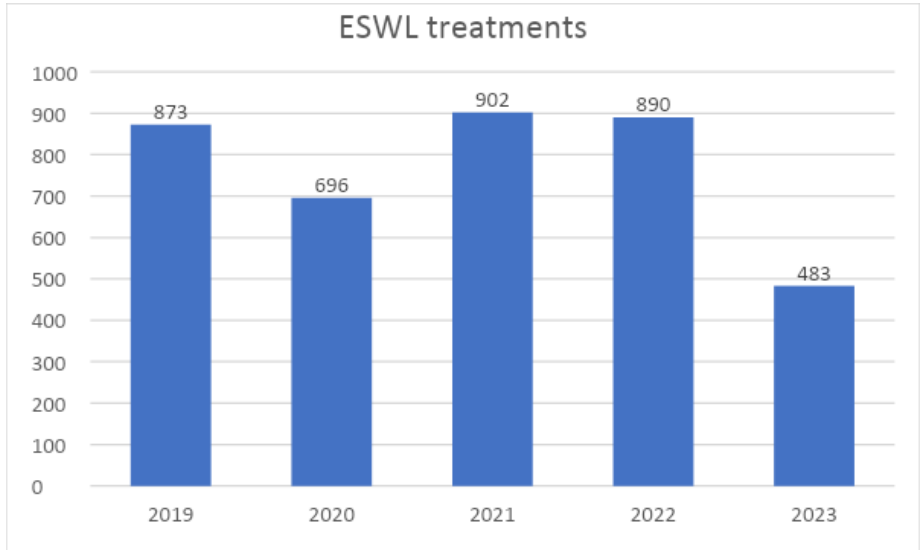
than 15 mm, or with growing stones on follow-up, and in those with symptomatic stones less than 15 mm in size. Obstruction or infections caused by stones are an indication for a more urgent intervention. Also, the patient's social situation, profession and preferences need to be considered when choosing between observation and active treatment.

## MATERIALS AND METHODS

The data from the protocol book of patients treated with extracorporeal shock wave lithotripsy (ESWL) in the Department of Urology was analyzed for a time period from January 2019 until November 2023. The data regarding number of procedures, stone size and position, patient age and relevant clinical information was collected. Data were analyzed using Microsoft Excel (Microsoft Corporation, Redmond, Washington, USA).

## RESULTS

There were a total of 3,844 procedures, over a period of almost 5 years. Figure 1 shows the distribution of procedures in each year. The average patient age was 52 years, and the average stone size was 0.9 cm. The stone location distribution is shown in figure 2. Figure 3 shows the proportion of repeated procedures, that is, the number of procedures required for stone destruction. One procedure was sufficient in 22% of patients, two in 21%, and three in 18% of patients. Others required more than three procedures. In 16% of patients, the procedure was canceled or interrupted because of radiotransparency on X-ray (10%), hypertension (3%) and pain (3%).



ESWL – extracorporeal shock-wave lithotripsy

Figure 1. Number of ESWL treatments during the years

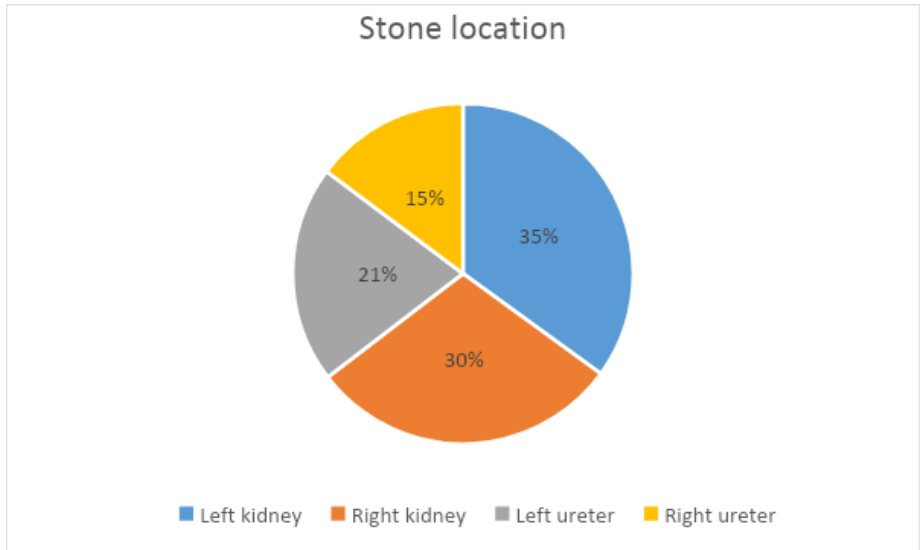


Figure 2. Distribution of stone locations

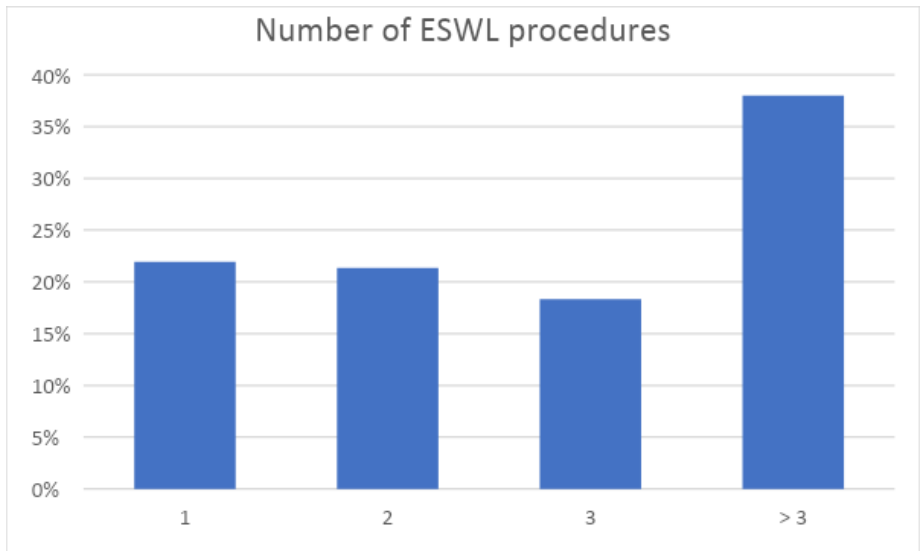


Figure 3. Number of ESWL procedures

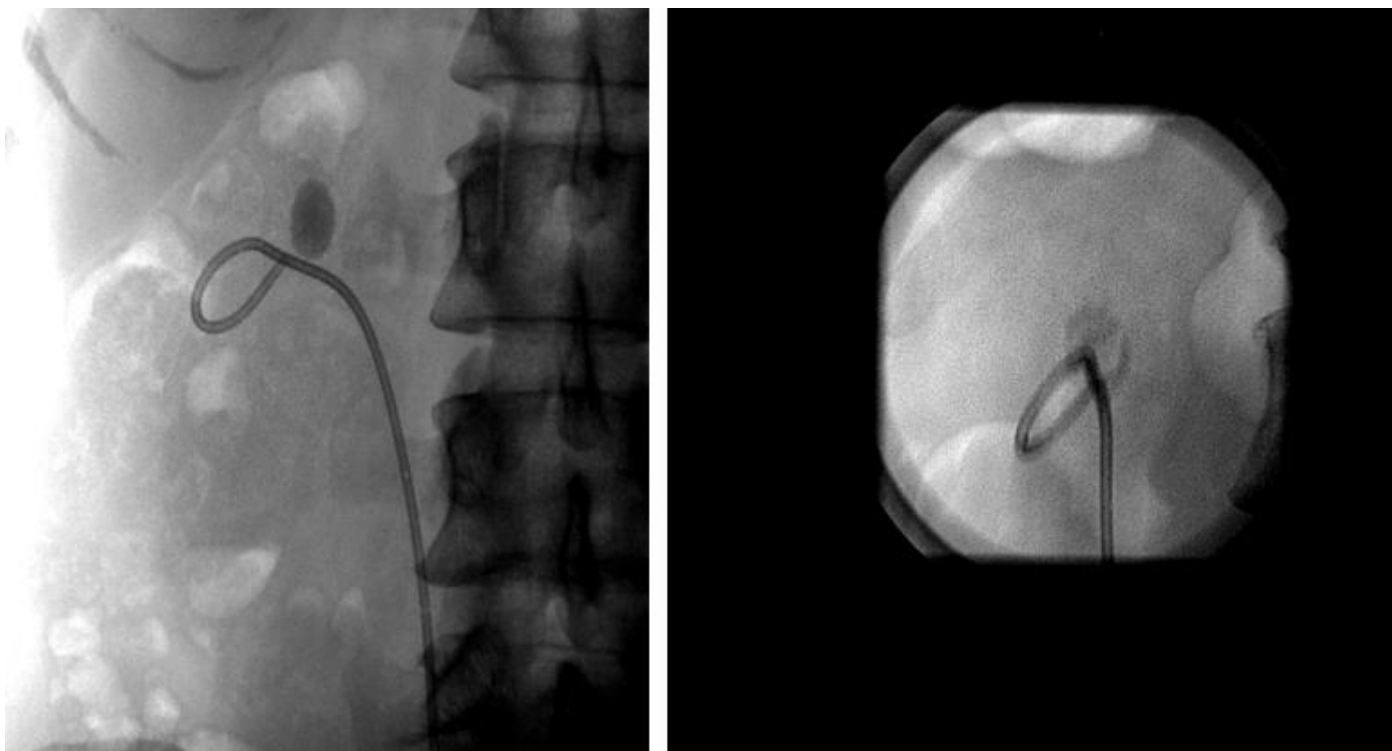


Figure 3. X ray imaging of 16 mm kidney stone before ESWL (on the left) and after ESWL, with visible fragmentation (on the right).

## DISCUSSION

Extracorporeal shock wave lithotripsy is a non-invasive method for the treatment of urolithiasis. The lithotripter device delivers shock waves to the targeted stone in the kidney or ureter. The beginning of ESWL dates to the middle of the last century and is linked to Claude Dornier. Dornier was a German scientist who did research for the aircraft industry and discovered shock waves, which resulted in the first device for extracorporeal shock wave lithotripsy (5). In the 1970s and early 1980s, clinical research began, that is, the introduction of the ESWL method into clinical practice (6). A few years later, ESWL became widely used as the standard treatment for kidney stones. Today, in addition to Dornier, other large manufacturers of medical equipment such as Siemens and Storz have ESWL devices that have treated millions of patients with urinary tract stones (7).

ESWL is routinely used in University Hospital Center Zagreb since 1987. Since 2013, all procedures are performed on the Siemens Lithostar device. It is organized as an outpatient procedure. Patients first come to our urinary tract stone center, where a medical history is taken, a physical examination is performed, and medical documentation is reviewed. If there is an indication for ESWL, patients are informed about ESWL treatment and they are scheduled for it. Depending on the number of patients and the capacity of the institution, up to 5 procedures per day are carried out. There is a visible increase in a number of procedures each year, with the exception of the 2020, during the COVID-19 pandemic.

The success of ESWL depends on the size and location of the stone, as well as the composition. The last determinant is the

properties of the lithotripter device itself. The result also depends on the habitus of the patient and the stone-skin distance. There is no consensus on the maximum energy applied and the number of shock waves (8). Higher energy can be applied to the ureteral stones, while the energy applied to kidney stones is lower. Lowering shock wave frequency to 60-90/min improves stone-free rates (SFR), and also lowers tissue damage (9). Reported complication rates vary between the studies, the most common being *steinstrasse* (4%-7%), regrowth of residual fragments (21%-59%), and renal colic (2%-4%) (10-12). Asymptomatic hematoma occurs in 4%-19%, while symptomatic occurs in less than 1% of cases (13). In this research, we didn't analyze exact complication rates, because of a vast number of patients and the fact that many patients came and are returned to the urology departments of other hospitals from Zagreb or from all over Croatia. However, we can state that the procedure is well tolerated by the patients, and the renal hematoma that requires hospitalization is a rare event. In the last year, we only have two cases of hematoma, and neither required intervention. Repeated sessions are feasible and often needed, even within one day for ureteral stones (14). Although ESWL is a valuable modality for the treatment of urolithiasis, with low complication rates and additional costs, it requires good patient selection. The first criterion is stone visibility on X-ray. In our study, in 10% of cases, the EWSL could not be performed, because of the invisibility of stones on X-rays. This could be because of the radiotransparency of the stones due to their composition, meteorism, or because of spontaneous expulsion. The second criterion is the total stone burden and

position. Intake of oral anticoagulants is also a contraindication, as well as uncontrolled hypertension. Other contraindications are pregnancy, urinary tract infections, and aneurysms of the aorta, renal or iliac vessels. Patients with ureteral stones larger than 10 mm could also be eligible for ESWL, but faster stone-free status could be achieved with a more invasive approach. Kidney stones larger than 20 mm are usually not good candidates for ESWL. For patients who do not meet the criteria, a more invasive endoscopic approach is required. In UHC Zagreb, we perform all kinds of operative treatment for urolithiasis, ureteroscopy (URS), flexible ureterorenoscopy (FURS), percutaneous nephrolithotomy (PCNL), and endoscopic combined intrarenal surgery (ECIRS) which is a combination of PCNL and FURS.

In isolated cases, we also use laparoscopic pyelolithotomy, while the open approach is rarely used.

Urolithiasis is a high-prevalence and high-recurrence disease. For many patients a non-invasive extracorporeal shock wave lithotripsy is the treatment modality of choice, offering good results with low complication rate. For patients with larger stones and higher stone burden, one of the more invasive methods could be a better choice. A good selection is needed in order to successfully treat patients with urolithiasis.

#### ACKNOWLEDGMENTS

Authors have nothing to acknowledge.

#### REFERENCES

1. Wimpissinger F, Türk C, Kheyfets O, Stackl W. The silence of the stones: asymptomatic ureteral calculi. *The Journal of urology*. 2007;178:1341-4; discussion 4. Epub 2007/08/21. doi: 10.1016/j.juro.2007.05.128.
2. Ray AA, Ghiculete D, Pace KT, Honey RJ. Limitations to ultrasound in the detection and measurement of urinary tract calculi. *Urology*. 2010;76:295-300. doi: 10.1016/j.urology.2009.12.015.
3. Heidenreich A, Desgrandschamps F, Terrier F. Modern approach of diagnosis and management of acute flank pain: review of all imaging modalities. *European urology*. 2002;41:351-62. Epub 2002/06/21. doi: 10.1016/s0302-2838(02)00064-7.
4. El-Nahas AR, El-Assmy AM, Mansour O, Sheir KZ. A prospective multivariate analysis of factors predicting stone disintegration by extracorporeal shock wave lithotripsy: the value of high-resolution noncontrast computed tomography. *European urology*. 2007;51:1688-93; discussion 93-4. doi: 10.1016/j.eururo.2006.11.048.
5. Dornier MedTech. Available at: <https://www.dornier.com/history/>. Accessed Nov 20th 2023.
6. Chaussy C, Schmiedt E, Jocham D, Brendel W, Forssmann B, Walther V. First clinical experience with extracorporeally induced destruction of kidney stones by shock waves. *J Urol*. 1982;127:417-420.
7. Storz Medical. Available at: <https://www.storzmedical.com/en/>. Accessed Nov 20th 2023.
8. López-Acón JD, Budía Alba A, Bahílo-Mateu P, Trassierra-Villa M, de Los Angeles Conca-Baenas M, de Guzmán Ordaz-Jurado D, et al. Analysis of the Efficacy and Safety of Increasing the Energy Dose Applied Per Session by Increasing the Number of Shock Waves in Extracorporeal Lithotripsy: A Prospective and Comparative Study. *Journal of endourology*. 2017;31:1289-94. doi: 10.1089/end.2017.0261.
9. Moon KB, Lim GS, Hwang JS, Lim CH, Lee JW, Son JH, et al. Optimal shock wave rate for shock wave lithotripsy in urolithiasis treatment: a prospective randomized study. *Korean journal of urology*. 2012;53:790-4. Epub 2012/11/28. doi: 10.4111/kju.2012.53.11.790.
10. Tan YM, Yip SK, Chong TW, Wong MY, Cheng C, Foo KT. Clinical experience and results of ESWL treatment for 3,093 urinary calculi with the Storz Modulith SL 20 lithotripter at the Singapore general hospital. *Scand J Urol Nephrol*. 2002;36:363-7. doi: 10.1080/003655902320783872.
11. Osman MM, Alfano Y, Kamp S, Haecker A, Alken P, Michel MS, et al. 5-year-follow-up of patients with clinically insignificant residual fragments after extracorporeal shock-wave lithotripsy. *European urology*. 2005;47:860-4. doi: 10.1016/j.eururo.2005.01.005.
12. Sayed MA, el-Taher AM, Aboul-Ella HA, Shaker SE. Steinstrasse after extracorporeal shockwave lithotripsy: aetiology, prevention and management. *BJU international*. 2001;88:675-8. doi: 10.1046/j.1464-4096.2001.02435.x.
13. Dhar NB, Thornton J, Karafa MT, Strem SB. A multivariate analysis of risk factors associated with subcapsular hematoma formation following electromagnetic shock wave lithotripsy. *The Journal of urology*. 2004;172:2271-4. doi: 10.1097/01.ju.0000143459.03836.2d.
14. Abdelbary AM, Al-Dessoukey AA, Moussa AS, Elmarakbi AA, Ragheb AM, Sayed O, et al. Value of early second session shock wave lithotripsy in treatment of upper ureteric stones compared to laser ureteroscopy. *World journal of urology*. 2021;39:3089-93. doi: 10.1007/s00345-020-03560-x.

