

# Treatment of Actinic Keratoses and Field Cancerization – Croatian perspective

Mirna Šitum<sup>1,2,3</sup>, Nika Franceschi<sup>1</sup>, Nikola Ferara<sup>\*1</sup>, Zdenka Šitum Čepnija<sup>4</sup>

<sup>1</sup> Department of Dermatology and Venereology, Sestre Milosrdnice University Hospital Centre, Zagreb, Croatia

<sup>2</sup> School of Dental Medicine, University of Zagreb, Croatia

<sup>3</sup> Croatian Academy of Sciences and Arts, Zagreb, Croatia

<sup>4</sup> Department of Dermatology and Venereology, University Hospital Centre Split, Split, Croatia

## ABSTRACT

Actinic keratoses (AKs) are the most common premalignant skin lesions, caused by chronic sun damage and accordingly, found on chronically sun-exposed skin, such as face, scalp, neck, hands, and forearms. Clinically, these lesions present as macules, papules or hyperkeratotic plaques on an erythematous background. In Caucasians over 60 years of age, the prevalence of AKs is up to 80%. The diagnosis is based on clinical and dermoscopic examination. The main concern with AKs is the risk of transformation into squamous cell carcinoma (SCC), therefore all lesions should be evaluated for treatment. Treatment options for AKs are divided into lesion-oriented and field-oriented treatments. Lesion-directed treatment modalities commonly involve cryosurgery/liquid nitrogen cryotherapy, surgery (shave, excision), and laser therapy, while field-directed treatments include topical agents, photodynamic therapy, chemical peels, field ablation with dermabrasion and CO<sub>2</sub> laser resurfacing. This review outlines the different types of treatments available, the characteristics, side effects, and benefits of each modality, and highlights the best treatment options, with a reflection on possibilities and limitations in the Republic of Croatia.

## OPEN ACCESS

### Correspondence:

Nikola Ferara  
nfera94@gmail.com

This article was submitted to RAD  
CASA - Medical Sciences  
as the original article

### Conflict of Interest Statement:

The authors declare that the research was conducted in the absence of any commercial or financial relationships that could be construed as a potential conflict of interest.

**Received:** 7 May 2024

**Accepted:** 3 June 2024

**Published:** 25 June 2024

### Citation:

Šitum M, Franceschi N, Ferara N, Šitum Čepnija Z. Treatment of Actinic Keratoses and Field Cancerization – Croatian perspective  
563=66-67 (2024): 38-47  
DOI: 10.21857/mwo1vcrojy

Copyright (C) 2024 Šitum M, Franceschi N, Ferara N, Šitum Čepnija Z. This is an open-access article distributed under the terms of the Creative Commons Attribution License (CC BY). The use, distribution or reproduction in other forums is permitted, provided the original author(s) and the copyright owner(s) are credited and that the original publication in this journal is cited, in accordance with accepted academic practice. No use, distribution or reproduction is permitted which does not comply with these terms.

**KEYWORDS:** actinic keratoses, field cancerization, treatment, Croatia

## SAŽETAK:

LJEČENJE AKTINIČKIH KERATOZA I ZLOČUDNE TRANSFORMACIJE – HRVATSKA PERSPEKTIVA

Aktiničke keratoze (AKS) najčešće su premaligne kožne lezije uzrokovane kroničnim oštećenjem sunčevih zraka, a prema tome se nalaze na kronično izloženoj suncu, kao što su lice, vlasište, vrat, ruke i nadlaktice. Klinički, te se lezije manifestiraju kao makule, papule ili hiperkeratoze na eritematnoj pozadini. U Kavkazijaca starijih od 60 godina prevalencija AKS-a iznosi do 80%. Dijagnoza se temelji na kliničkom i dermoskopskom pregledu. Glavni razlog za zabrinutost kod AKS-a je rizik od transformacije u karcinom skvamoznih stanica (SCC), stoga je potrebno procijeniti sve lezije radi liječenja. Opcije liječenja AKS-a podijeljene su na tretmane usmjerene na lezije i terenske tretmane. Načini liječenja usmjereni na lezije obično uključuju kriokirurgiju/krioterapiju tekućim dušikom, kirurgiju (brijanje, eksciziju) i lasersku terapiju, dok terenski tretmani uključuju topikalna sredstva, fotodinamičku terapiju, kemijske pilinge, ablaciju polja dermoabrazijom i CO<sub>2</sub> lasersko obnavljanje. U ovom se pregledu opisuju različite vrste dostupnih tretmana, značajke, nuspojave i koristi svakog modaliteta te se ističu najbolje opcije liječenja, s osvrtom na mogućnosti i ograničenja u Republici Hrvatskoj.

**KLJUČNE RIJEČI:** aktinička keratoza, područna zloćudna transformacija, liječenje, Hrvatska

## INTRODUCTION

Actinic keratoses (AKs) are the most common premalignant skin lesions and the third most common reason for dermatological consultation, after acne and dermatitis (1). They are caused by atypical proliferation of epidermal keratinocytes induced by chronic ultraviolet (UV) radiation. Therefore, in 75% of cases they occur on sun-exposed skin of older, fair-skinned individuals (2,3), predominantly affecting the face, neck, hands and forearms (4). The typical clinical presentation of an AK is an erythematous macule, papule or scaly patch or plaque, usually with poorly defined borders and varying degree of hyperkeratosis, sometimes better identified by touch than visual inspection. Lesions are usually numerous and signs of sun damage such as pallor, wrinkles, hyperpigmentation, telangiectasias and xerosis are visible on adjacent skin. There are several clinical variants of AKs, such as atrophic, classic, hypertrophic, cutaneous horn, pigmented lichenoid and actinic cheilitis (5). Diagnosis is usually based on clinical examination, including palpation, dermoscopic findings and medical history (6). The sensitivity and specificity of dermoscopy in the diagnosis of classic AKs are 98% and 95%, respectively. Classic AKs dermoscopically exhibit a red pseudonetwork, white scales, yellowish keratotic follicular openings, also known as the “strawberry pattern”. AKs are premalignant lesions confined to the epidermis and, if left untreated, can progress, invade deeper layers of the skin, and eventually metastasize. The number of AKs that progress to SCCs is unknown and depends on the presence of risk factors but is estimated to occur in 0.075% to 0.096% of per lesions per year (7,8). Dermoscopy is essential in identifying specific dermoscopic patterns associated with different stages of AK development, especially early signs of invasive SCC, such as the presence of coiled/glomerular or polymorphous vessels and white circles (9,10). Biopsy should be considered for rapidly growing lesions, lesions greater than one centimeter in diameter, indurated, ulcerated or tender lesions, and those that do not respond to appropriate local treatment (eg. persisting for 8 to 12 weeks after cryotherapy) (6). As it is impossible to predict the risk of progression to SCC for an individual AK, treatment of AKs is of paramount importance and follow-up is recommended (11). In this review we are going to present all treatment options for AK and FC, with a reflection on possibilities, limitations, and the experience in the Republic of Croatia.

## FIELD CANCERIZATION

According to a literature review by a committee of eight expert European dermatologists, field cancerization (FC) is clinically defined as: “an anatomical area with or adjacent to AKs and visibly sun-damaged skin identified by at least two of the following signs: telangiectasia, atrophy, pigmentation disorders and sandpaper. It is unclear if a visible AK is needed for field cancerization” (12). Field cancerization does not have a separate code in the International Classification of Diseases, 10th revision, Clinical Modification, which underlines the fact that it is not considered

a separate diagnosis from AK. However, multiple AKs are not always considered field cancerization, as patients with field cancerization have a disease process that behaves differently, more often have broad and hyperkeratotic scaly lesions and a significantly higher risk of invasive SCC compared to patients with AKs only. In this context, a group of US authors proposed an appropriate definition of field cancerization, defined as multifocal clinical atypia characterized by AKs or SCCs in situ with or without invasive disease, occurring in a field exposed to chronic UV radiation (13), giving a rationale for active treatment of field cancerization.

## TREATMENT – GENERAL PRINCIPLES

The goals of ideal treatment of AKs are to eradicate evident and subclinical lesions, prevent progression to SCC and reduce recurrences (11, 14). Treatment of AKs can be either lesion- or field-directed. Lesion-directed treatments target individual AKs, whereas field-directed treatments have the advantage of treating multiple, widespread, and subclinical AKs that may occur within a field of chronic sun damage, commonly referred to as field cancerization (15). Side effects such as erythema, edema, blistering, erosions, crusting, pigment changes, and scarring, as well as sensations such as burning, pain and pruritus are expected with all treatments. Healing may take a few days to weeks, depending on the location and number of lesions treated. More than one treatment is usually required (11). Lesion-directed treatment modalities commonly involve focal ablative procedures of a clinically evident lesion, such as cryosurgery/liquid nitrogen cryotherapy, surgery (shave, excision), and laser therapy (5). On the other hand, field-directed treatments are indicated for the treatment of field cancerization. These treatments can also be used as an alternative to lesion-directed treatments in patients with multiple AKs, poor response to treatment and lesion recurrence (16). Field-directed treatments include topical agents (eg. imiquimod, fluorouracil), photodynamic therapy, chemical peels, field ablation with dermabrasion and CO<sub>2</sub> laser resurfacing (17). Figure 1 summarizes management of AKs and FC.

## CRYOTHERAPY

Cryosurgery/liquid nitrogen cryotherapy is a widely available, relatively easy to administer, rapid and effective lesion-directed treatment for AKs. It is recommended as a first-line treatment for one or a few isolated AKs (11,18). However, it should be performed when the clinical diagnosis of AK is certain or after histopathologic confirmation, as this procedure does not produce a specimen for histopathologic confirmation. It is usually performed by applying liquid nitrogen with a cotton-tipped applicator or spray during a single freeze-thaw cycle also including a one millimeter wide margin of normal skin, for a period of 5 to 40 seconds, depending on size of the lesion and keratiniza-

tion (19). The destructive effect of freezing is achieved in two ways: immediate cell destruction or direct effect (osmotic shock, intracellular ice formation, apoptosis, autophagy, necrosis) and delayed cell destruction or indirect effect (avascular necrosis, immune reaction). Cell destruction is greatest near the site of liquid nitrogen application and gradually decreases at the periphery. For maximum effect, it is best to create a temperature of  $-40^{\circ}\text{C}$  at the tumor margin. It is strongly recommended to perform a second freezing after the first thawing (19,20). The large differences in reported clearance rates may be related to differences in cryotherapy administration (freeze time, number of freeze-thaw cycles, contact versus spray technique) (21). Overall, cryosurgery is reported to cure 57% to 98.8% of AKs, followed for three months to 8.5 years (11). Multicentric studies have also shown that cryotherapy is preferable to ablative  $\text{CO}_2$  laser for the treat-

ment of isolated AKs of the face and scalp (22). When comparing cryotherapy alone or in combination with other topical treatments (ie, imiquimod, 5-fluorouracil, diclofenac), response rates for cryotherapy alone ranged from 39 to 76% compared to 73 to 89% for combination therapy (23). Side effects following cryotherapy include edema, erythema, pain, blistering (serohe-morrhagic blistering develops 12 to 36 hours following the procedure), and changes in skin pigmentation, with hypopigmenta-tion being more common than hyperpigmentation. Scarring is rare, while permanent hair loss may occur if the treatment is per-formed on the scalp. One of the main drawbacks of cryotherapy is the lack of standardization, so the efficacy is highly dependent on the physician and the chosen protocol (19,21). Cryotherapy is contraindicated in patients with cryoglobulinemia or cold urticaria, and for lesions requiring histopathologic analysis to

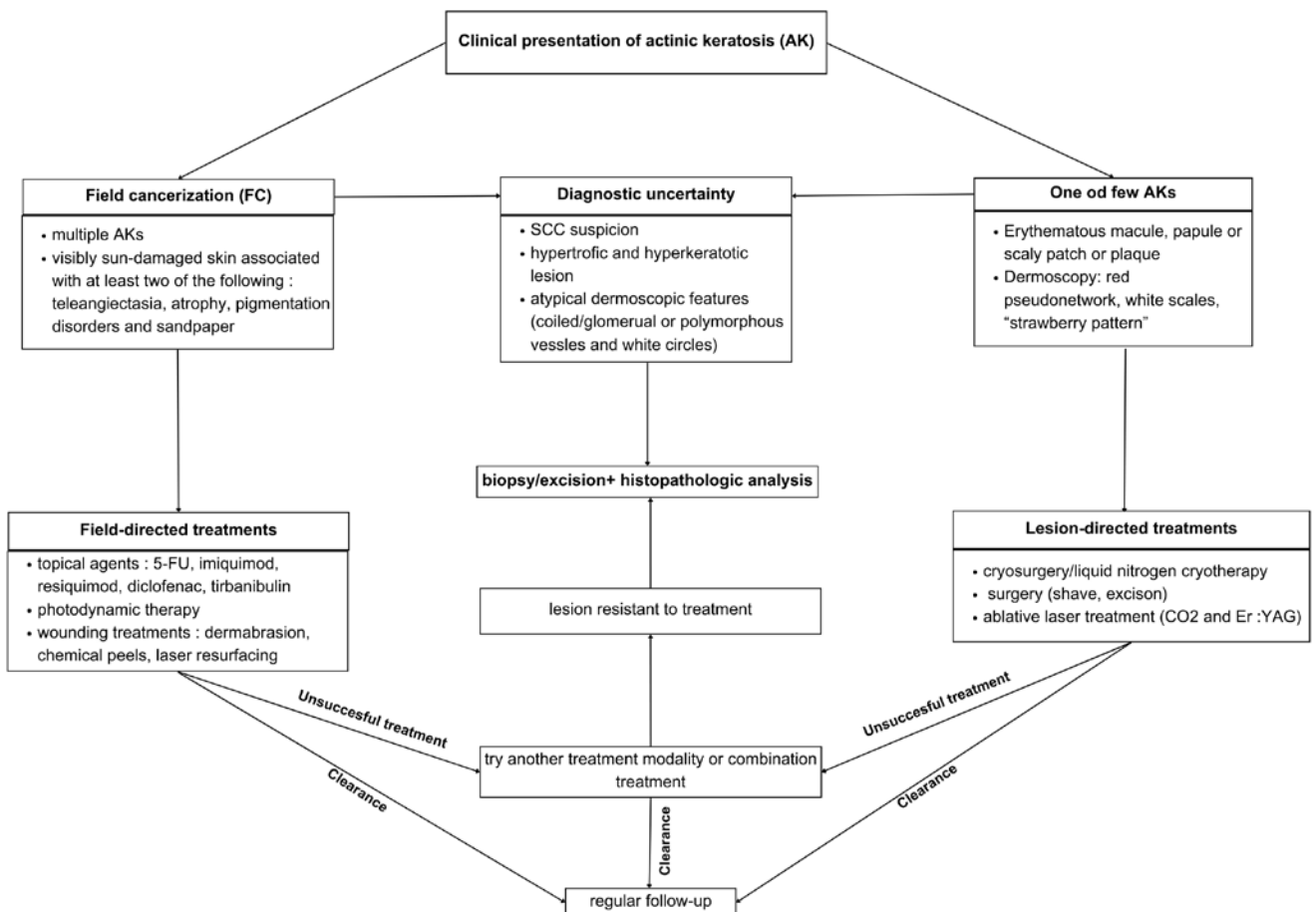


Figure 1. Management of AKs and FC in a practical algorithm.

exclude malignancy (5). Cryotherapy is, by far, the most used method of treating actinic keratoses in the Republic of Croatia. Coming from the personal experience of the authors, the major issue about its use is, the above mentioned, lack of standardization. Physicians often use it in insufficient scope and intensity, which often results in repeated visits for follow-up examinations. The main reason for this is the patient's fear of the cosmetic effect, but also possible uncertainty in diagnosing actinic keratoses. Patient should be given an informative explanation about how the treated area could look and what to expect.

### SURGICAL TREATMENTS

Surgical treatment is often used for hyperkeratotic and hypertrophic AKs, those that have not responded to other treatments or in cases where the diagnosis is uncertain, as it allows specimen collection and subsequential histopathologic analysis. This is particularly important if there is high suspicion of SCS (20). These procedures require local anesthesia and can cause bleeding and scarring. Curettage is the most frequently performed surgical procedure in AK management and is best suited for solitary lesions. It can be combined with other destructive procedures, such as cryosurgery (4). Electrodessication following curettage can help with hemostasis and for defining lesion margins (24). However, compared to complete excision, shave excision and curettage followed by other treatments usually do not provide an adequate sample to assess whether a lesion is invasive (4).

### LASER THERAPY

Laser treatment is another effective lesion-directed treatment. However, it can also be used as a field-directed treatment in the form of laser resurfacing. Laser therapy can be ablative or non-ablative, depending on the type of laser used—ablative laser (CO<sub>2</sub> and erbium yttrium aluminum garnet) or non-ablative fractional laser systems. When ablative laser systems are used, the superficial layers of the skin are ablated, including the epidermal and superficial dermal actinic damage. Re-epithelialization occurs from unaffected skin and keratinocytes from follicles. When using CO<sub>2</sub> lasers, the additional positive cosmetic results are due to removal of not only the epidermis, but also part of the dermis, and the thermal effect just below the ablated layer, which induces tissue tightening and collagen shrinkage. The thermal effect is also responsible for the absence of intraoperative bleeding (coagulation) and less pain (ablation of superficial nerves) but poses a risk of scarring. Non-ablative lasers (eg. erbium glass lasers) induce a dermal regeneration response by producing a vertical coagulation column (microthermal zone) located mostly in the dermis, leaving the stratum corneum intact (25). Laser therapy appears to be quite effective with a 90% response rate in treatment of AKs and recurrence rate of 10-15% at 6 months (24). Possible side effects of laser treatment include pain, inflammation, pigment change and delayed skin healing.

Laser treatment is generally one of the most effective treatments for AKs, although it is expensive and has a higher learning curve compared to other lesion-directed treatments (20,25). In the Republic of Croatia laser treatment of actinic keratoses and field cancerization is not covered by Croatian Health Insurance Fund and is therefore only present in the settings of private practice. Because of this, there is scarce information about its use and effect in treating AKs and FC.

### 5-FLUOROURACIL (5-FU)

5-fluorouracil (5-FU), a pyrimidine analogue, is a chemotherapeutic anticancer agent that is associated with inhibition of thymidylate synthase and incorporation into RNA and DNA, which interferes with DNA synthesis, thereby destroying actinic cells. There are various formulations of 5-FU, such as 1% and 5% cream or solution, 2% solution and 0.5% cream. In Europe the most used formulation is 5% 5-FU cream, usually applied twice daily for four weeks (20). 5% 5-FU cream is the only available formulation in Croatia. Based on the available data, 5-FU appears to be the most effective topical agent for the treatment of AKs (26). Its superiority compared to other topical agents was recently confirmed in a large, multicenter, single-blind, randomized, head-to-head trial, conducted by a group of Dutch authors and involving 624 patients. At 12 months post-treatment, 5% 5-FU cream was significantly more effective than other agents in patients with multiple lesions on the head, with a cumulative probability of treatment success of 74.7% (95% confidence interval (CI)) for 5-FU, and 53.9% (95% CI), 37.7% (95% CI) and 28.9% (95% CI) for imiquimod, photodynamic therapy and ingenol mebutate, respectively. Another important aspect of this study is the inclusion of grade III or severe lesions (very thick or obvious AKs), which has not been considered in most other studies investigating the efficacy of field-directed treatments (27). Additionally, 5-FU can be combined with other agents, such as calcipotriol and salicylic acid. Topical application of 5-FU/calcipotriol appears to be an effective immunotherapy for AKs, with even better results than 5-FU alone. In a blinded prospective cohort study, a short course treatment with 5-FU/calcipotriol on the face and scalp was associated with induction of robust T-cell immunity and tissue resident memory T-cells against AKs and a significantly lower risk of SCC at 3 years post-treatment (28). This additional carcinoma-preventing property makes it an ideal field-directed treatment. A fixed combination of 0.5% 5-FU and 10% salicylic acid was initially introduced for the treatment of hyperkeratotic AKs of the head and neck, on the rationale that salicylic acid should improve the penetration of 5-FU due to its well-known keratolytic properties. Although the efficacy of this combination therapy has not yet been established, recent reports are promising. One observational study reported complete clearance of 50% of treated lesions and partial clearance of 28% of the treated lesions at week 4; at 12 weeks, these

results were 84% and 8%, respectively. The combination of 5-FU and salicylic acid has been shown to be an effective treatment for mild to moderate AKs (29).

In the Republic of Croatia 5% 5-FU cream belongs to the Basic list of medicines, which means that for the most part, treatment with this agent is covered by health insurance. Because of this, and the substantial clearance rate, 5% 5-FU cream is the most prescribed topical agent in treatment of FC in our country. Also, it is often prescribed for AKs of large surfaces, superficial basal cell carcinomas and Bowen's disease. There is an established procedure for presenting photo documentation of treatment phases to achieve the highest possible adherence to therapy.

### IMIQUIMOD AND RESIQUIMOD

Another field-directed treatment is imiquimod, a synthetic imidazoquinolone that has a potent immune response modifying activity when used topically. It is a toll-like-receptor (TLR) agonist, inducing apoptosis and the release of cytokines and chemokines, such as tumor necrosis factor  $\alpha$  (TNF- $\alpha$ ), interferon- $\gamma$  (IFN- $\gamma$ ), interleukins, and granulocyte-macrophage colony-stimulating factor (GM-CSF). The release of these pro-inflammatory mediators causes a great influx of inflammatory cells into the lesion, resulting in its destruction by natural killer cells and cytotoxic T lymphocytes (30). The mechanism of action may explain why, in addition to AKs, imiquimod is also used for treating other skin conditions such as genital or perianal warts caused by human papillomavirus (HPV) or basal cells carcinoma (BCC). Imiquimod is available as 2.5%, 3.75% and 5% cream. In Croatia imiquimod is available only as a 5% cream. A 5% concentration should be applied to an area of no more than 25 cm<sup>2</sup> on the face and scalp, three times a week for 4 weeks over a period of 16 weeks. Lower concentrations, 2.5% and 3.5%, can be applied daily in a 6-week regimen: 2 weeks of treatment, followed by 2 weeks off and another 2 weeks of treatment (20). The 5% formulation is preferred for BCCs, while the 3.5% formulation is a reasonable option for AKs and field cancerization, as it can be applied to a larger surface and has fewer side effects than the 5% formulation, while having similar efficacy. The 3.5% imiquimod formulation has a clearance rate of 35.6% and recurrence rate of 20.9% 12 months post-treatment (30). Recently, a small study presented an interesting feature of imiquimod 3.75% cream detecting clinically invisible (subclinical) actinic damage. Experimental application of 3.75% imiquimod cream to chronically UV-exposed skin induced a faint, but visible inflammation, a sign of binding of imiquimod to TLR-7 on monocytes and macrophages, which mediates activation of intrinsic and acquired immunity through activation of cytokines with antineoplastic capabilities. In other words, imiquimod caused a skin reaction at sites of early, clinically invisible, malignant cells (31). In Croatia, 5% imiquimod cream is listed in the Supplementary list of medi-

cines – therefore it is substantially less prescribed for treatment of AKs and FC in comparison to 5-FU.

Resiquimod, just like imiquimod, belongs to the class of imidazoquinolines and is a TLR-7 and TLR-8 agonist that activates myeloid and plasmacytoid dendritic cells. Resiquimod is available in concentrations of 0.01, 0.03, 0.06, or 0.1%, with greatest efficacy observed when used three times a week for four weeks. Given its pharmacodynamic profile, resiquimod may potentially achieve greater efficacy than imiquimod. A recent multi-center, partly placebo-controlled, double-blind clinical trial found that 0.03% and 0.01% resiquimod gel were effective treatments for the AKs of balding scalp, forehead, and face. Additionally, dosing regimens with erosions as a biological endpoint proved to be effective and may be suitable for tailored treatment of AKs (32). Unfortunately, resiquimod is not available in Croatia.

### DICLOFENAC

Diclofenac is a nonsteroidal anti-inflammatory drug (NSAID) that has anti-inflammatory, analgesic, and antipyretic properties. The likely mechanisms of its anti-tumor effects are inhibition of cyclooxygenase 2 activation, which is overexpressed in SCCs, and inhibition of prostaglandin E2, which is associated with tumor angiogenesis and cell proliferation, as well as binding to the nuclear receptor PPAR $\gamma$  (partial agonist of peroxisome proliferator-activated receptor gamma), whose activation inhibits cancer cell growth (16, 33). It is currently only available in a combination formulation of 3% diclofenac gel in 2.5% hyaluronic acid and is routinely applied twice daily for 60 to 90 days, making it one of the longest treatments for AKs. Although slightly less effective than other topical treatments (e.g., 5-FU or imiquimod) with a 54 to 63% clearance rate, it is very well tolerated and causes only mild skin irritation, making it an alternative to other, more aggressive topical treatments and suitable for the management of AKs (16). In Croatia diclofenac is not available for treatment of AKs and FC. There is only formulation of diclofenac as a pain-relief gel.

### INGENOL MEBUTATE

Ingenol mebutate is an active substance isolated from milkweed (*Euphorbia peplus*), historically known as a home remedy for BCCs, warts and AKs due to its cytotoxic activity and ability to affect cell differentiation. Although the true mechanism of anticancer activity had not been fully elucidated, there are two plausible mechanisms; direct cytotoxic activity (direct tumor cell death resulting in necrosis) and immune-mediated mechanism (antibody-dependent cellular cytotoxicity mediated by neutrophils) (34, 35). Despite being promising treatment agent, it has been proved that ingenol mebutate (in the form of a gel) increased the risk of skin cancer, particularly SCC in the treatment area. As a result of this, in April 2020, the European Medicines

Agency (EMA) issued a press release clearly stating that the risks of ingenol mebutate outweighed the benefits, suspending it from the market in the European Union (36).

### TIRBANIBULIN

Tirbanibulin is a microtubule-targeting agent that has shown potent anti-proliferative and anti-tumoral effects in-vitro and in-vivo by inducing cell cycle arrest and ultimately apoptotic cell death (37). It works by inhibiting tubulin polymerization and disrupting Src kinase signaling, the two pathways often upregulated in AKs and SCCs (38). Tirbanibulin, available as a 1% ointment, is a novel agent approved by the European Medicines Agency (EMA, 2021) and the Medicines and Healthcare Products Regulatory Agency (MHRA, 2021) for 5-day topical field-directed treatment of non-hyperkeratotic, non-hypertrophic AKs on the face and scalp in adults. A recent review of the efficacy and safety of different AK and FC treatments showed that tirbanibulin is superior to diclofenac in complete clearance rate and has similar efficacy as well-established treatments, such as photodynamic therapy, imiquimod, cryotherapy and 5-fluorouracil, with significantly lower rates of serious local skin reactions. Potential advantages over existing treatments are the short duration of treatment with once-daily application over five days, a good safety profile and efficacy comparable to existing topical treatments (39). Although available in Croatia, there is scarce use of this agent, mostly because of high treatment cost.

### PHOTODYNAMIC THERAPY

Photodynamic therapy is an effective treatment for AKs and field cancerization. In contrast to some agents used for topical treatment of AKs, it has a clear mechanism of action using visible light to react with photosensitizing chemical compounds, 5-aminolevulinic acid (ALA) and methyl-aminolevulinate (MAL) to generate active oxygen species responsible for the apoptosis of skin cancer cells. This treatment exploits the pathological property of cancer cells to accumulate protoporphyrin IX, the production of which is induced by ALA and MAL (40). One of the most convenient treatment executions is the use of daylight as part of daylight photodynamic therapy, whereby MAL or ALA cream is applied to the affected area and removed after a 2-hour exposure to natural daylight (20). Photodynamic therapy has a clearance rate of 82 to 91% and a recurrence rate of 53 to 64% at 12 months post-treatment, making it as effective as 5-FU or even more effective. The disadvantages of this treatment are the cost, time and severe pain associated with application (16). The use of photodynamic therapy in Croatia has been largely limited by difficulties in import of photosensitizing compounds (ALA and MAL). Additionally, many patients in the past requested cessation of treatment due to unbearable pain.

### WOUNDING TREATMENTS

Recently, wounding treatments such as dermabrasion, microneedling, chemical peeling, and fractionated laser resurfacing have been shown to restore IGF-1/IGF-1R (insulin-like growth factor-1/insulin-like growth factor-1 receptor) signaling in geriatric skin and suppress the propagation of damaged keratinocytes. In contrast to well-established topical treatments for AKs and field cancerization, which target already altered cells in precancerous lesions, wounding therapies have the potential of preventing malignant transformation (41).

### CHEMICAL PEELS

Topical exfoliative agents, alone or combined, are used to induce controlled cutaneous injury leading to epidermal turnover and collagen regeneration. In addition to their cosmetic effects, these agents can also be used in the treatment of AKs and field cancerization, because of their ablative nature, which has the potential to ablate premalignant cells (42). Chemical peels can be superficial (only penetrating the epidermis), medium-depth (penetrating the epidermis and papillary dermis) and deep (penetrating into the mid-reticular dermis). Usually, different groups of chemical peels can be combined to achieve the desired treatment goal (43). For example, Jessner's solution, a superficial peel consisting of resorcinol, salicylic acid and lactic acid, and 35% trichloroacetic acid (TCA), as a medium-depth peel. In one small split-face trial, the combination of Jessner's solution and 35% TCA in a single application was almost as effective in clearing AKs on the face as a 4-week treatment with 5% imiquimod cream (79.1% clearance with chemical peel vs 72.8% with imiquimod). Although both treatments were effective, chemical peels were more effective, easier to apply (shorter treatment duration) and resulted in greater patients' satisfaction (44). In addition to combination chemical peels, there are also sequential peels, in which wounding agents are applied sequentially, for example Jessner's solution followed by TCA. One of the medium-depth peel options for field cancerization treatment is the Brody peel, a sequential peel in which a solid CO<sub>2</sub> slush is followed by 35% TCA (45). In general, chemical peels seem valid field-directed treatments, and in the context of awareness that field cancerization needs to be adequately treated, these treatments are likely to be more widely recognized.

### FRACTIONATED LASER RESURFACING

Fractionated laser resurfacing has been extensively used for the treatment of photoaging, acne scarring and dyschromia. The rationale behind laser resurfacing for the treatment of AKs and field cancerization is based on removing the superficial layers of the skin and allowing re-epithelialization with healthy keratinocytes. According to a recent review regarding the efficacy of laser resurfacing compared to existing treatments for AKs, laser

resurfacing monotherapy has been shown to be at least as effective or more effective than 5-FU as field therapy and as effective as a 30% TCA peel in reducing AKs. However, there are still not enough studies to draw definitive conclusions about its efficacy (46).

### DERMABRASION

Dermabrasion is a skin resurfacing technique that has been used in dermatology for more than 100 years to treat various skin conditions (41). It is performed using a portable hand-held dermabrader with either wire brushes, diamond fraises, or serrated wheels for precise treatment. Although dermabrasion is an old technique, a carefully designed study by a group of American authors was the first to demonstrate how it restores a more youthful phenotype and induces a reversible molecular signature that can suppress the characteristic geriatric pro-carcinogenic ultraviolet response (41). Recently, a group of Chinese authors presented dermabrasion combined with photodynamic therapy (D-PDT) as a new option for the treatment of AKs and non-melanoma skin cancers (NMSC) - SCC, nodular BCC, Bowen disease. In their study only two patients with three AKs experienced recurrence after 12 months and 34 out of 40 patients (including those with NMSCs) treated with D-PDT reported excellent or good cosmetic results, proving that pretreatment with dermabrasion enhances the effect of PDT, making it suitable for management of thicker lesions (47). However, over all the effectiveness of dermabrasion depends heavily on the skill of the practitioner, and the cosmetic results can sometimes be unsatisfactory.

### RETINOIDS

Although retinoids are not considered conventional therapy for AK and FC treatment, they can help decrease the number of damaged or precancerous cells due to their effect on oxidative stress and cell differentiation (24). Retinoids can be used both topically and orally, with oral (systemic) retinoids mainly used for skin cancer chemoprevention in immunocompromised patients and are suitable for patients with multiple AKs. Isotretinoin is one of the most used retinoids and can be used as a 0.1% topical agent twice daily for six months or orally at a dose of 20 mg daily for three weeks (30). Combination therapy consisting of oral isotretinoin 20 mg and 5-FU once daily, also known as “turbo therapy”, has shown good efficacy (24).

### PREVENTION

All patients with AKs should be advised to apply protective measures against UV radiation: wearing appropriate clothing, hats, using sunscreens with a high sun protection factor (SPF > 30), avoiding strong and prolonged exposure to sunlight, sunbed use. Secondary prevention is important in patients at high risk of multiple AKs, field cancerization or immunosuppression, and includes prophylactic treatment with photodynamic therapy,

5-FU or imiquimod. Studies show that treatment with 5% 5-FU cream twice daily for 4 weeks reduces the number of AKs, the need for additional lesion-oriented treatments and leads to a 75% reduction in the risk of developing SCC (48). Several studies have examined the use of systemic chemoprevention in high-risk populations. Investigated agents included oral retinoids, NSAIDs, capecitabine, dietary supplements and vitamins (nicotinamide,  $\beta$ -carotene). Oral nicotinamide (vitamin B3) at a dose of 500 mg twice daily has been shown to reduce the development of SCC by 30% in immunocompetent individuals with confirmed keratinocyte carcinomas in the past five years (49). However, there are still no recommendations for chemoprevention of skin cancers.

### CHOOSING TREATMENT OPTIONS

There is no standard treatment for AKs. Physicians should decide considering both the lesions (number, distribution, location, histology) and patient characteristics (patient's preferences, age, compliance, immune status, cost). As treatment of these lesions is usually a long-term process for most patients, accompanied by a certain degree of discomfort and difficulty, the decision on the best treatment modality should be made jointly by the physician and patient. In our review, we analyzed possible treatment options based on indications and clinical presentation. Based on a review of the literature and our clinical experience, cryotherapy remains the gold standard for solitary or few AKs. It is a fast, effective, easy to administer and widely available treatment. Surgical treatment is irreplaceable in the assessment of malignancy of a solitary lesion in cases of diagnostic uncertainty, but usually only complete excision provides an adequate histopathological specimen. Biopsy should be considered for rapidly growing lesions, lesions greater than one centimeter in diameter, indurated, ulcerated or tender lesions, and those unresponsive to previous treatment.

All field-directed therapies used showed a short-term reduction in actinic keratosis, with 5-FU and PDT being the most effective methods for short-term clearance. Clearly, further studies with longer follow-up periods are needed to assess the effect of topical therapies on the long-term incidence of skin cancer, as best illustrated by the case of ingenol mebutate, the use of which has been associated with an increased incidence of keratinocyte carcinomas (SCC, Bowen's disease), leading to its withdrawal from the market in the EU. Adverse effects following topical treatment of AKs, and FC are mostly local and are observed for all the treatments used. They include erythema, ulceration, crusting, blistering, pruritus, and others and, in most cases, are mild and transient. Scarring and pigmentation can be irreversible adverse events. Systemic side effects are rare but can occur, for example flu-like symptoms after treatment with imiquimod. Diclofenac can be considered least effective, but it has an extremely good tolerability and high safety profile, with almost no systemic side

effects observed. Imiquimod and 5-FU are more effective, but are usually accompanied by moderate to severe reactions at the site of application, most of which resolve without sequelae (50). An unpleasant adverse event following photodynamic therapy is pain and possible photosensitization of the skin<sup>30</sup>. Further studies are needed to find a treatment that could achieve the best result in clinically visible lesions and a durable result for field cancerization, with fewer side effects and shorter duration to avoid poor patient compliance.

### CONCLUSION

Treatment of AKs and FC in Croatia relies mostly on the use of cryotherapy and 5% 5-FU cream. Just like in other countries, the use of cryotherapy lacks standardization and is often used with an insufficient intensity, resulting in lower clearance rate and repeated check-ups. 5% 5-FU cream is the most prescribed agent for treatment of FC and an established procedure for presenting photo documentation of treatment phases contributes to high

adherence to the therapy. 5% imiquimod cream in our country is not listed on the Basic list of medicines, which is why it is not prescribed as often as 5-FU cream. Following EMA's suspension, ingenol mebutat is no longer available in Croatia. Despite being respectable treatment modality for FC and AKs, photodynamic therapy is not routinely used in Croatia, due to the difficulties in the import of photosensitizing chemical compounds (ALA and MAL). Other treatment modalities, including laser, are not covered by medical insurance and their use is contained in the private practice. From our point of view, there is a great potential in use of chemical peels for treatment of AKs and FC in hospital settings in Croatia, mostly because some of the agents are already being used for cosmetic purposes and the treatment is supervised by an expert physician. From our experience, in some cases, no treatment is also a valid approach, especially in older patients, in whom there would be more harm than benefit from conducting the treatment. However, in these cases more frequent follow-ups are essential to closely monitor for SCC development.

### REFERENCES

- Warino L, Tusa M, Camacho F, Teuschler H, Fleischer AB Jr, Feldman SR. Frequency and cost of actinic keratosis treatment. *Dermatol Surg* 2006 Aug; 32(8): 1045-9.
- Heaphy MR Jr, Ackerman AB. The nature of solar keratosis: a critical review in historical perspective. *J Am Acad Dermatol* 2000 Jul; 43(1 Pt 1): 138-50.
- Lober BA, Lober CW. Actinic keratosis is squamous cell carcinoma. *South Med J* 2000 Jul; 93(7): 650-5.
- de Berker D, McGregor JM, Mohd Mustapa MF, Exton LS, Hughes BR. British Association of Dermatologists' guidelines for the care of patients with actinic keratosis 2017. *Br J Dermatol* 2017 Jan; 176(1): 20-43.
- Reinehr CPH, Bakos RM. Actinic keratoses: review of clinical, dermoscopic, and therapeutic aspects. *An Bras Dermatol* 2019 Nov-Dec; 94(6): 637-57.
- Kandolf L, Peris K, Malvey J, et al. European consensus-based interdisciplinary guideline for diagnosis, treatment and prevention of actinic keratoses, epithelial UV-induced dysplasia and field cancerization on behalf of European Association of Dermato-Oncology, European Dermatology Forum, European Academy of Dermatology and Venereology and Union of Medical Specialists (Union Européenne des Médecins Spécialistes). *J Eur Acad Dermatol Venereol*. Published online March 7, 2024. doi:10.1111/jdv.19897
- Cockerell CJ. Histopathology of incipient intraepidermal squamous cell carcinoma ("actinic keratosis"). *J Am Acad Dermatol* 2000 Jan; 42(1 Pt 2): 11-7.
- Marks R, Rennie G, Selwood TS. Malignant transformation of solar keratoses to squamous cell carcinoma. *Lancet Lond Engl* 1988 Apr 9; 1: 85-9.
- Šitum M, Goren A. Malignant epidermal tumors. In: *Dermatovenerology textbook and atlas*. Medicinska naklada; 2021. Str. 378-87.
- Zalaudek I, Argenziano G. Dermoscopy of actinic keratosis, intraepidermal carcinoma and squamous cell carcinoma. *Curr Probl Dermatol* 2015; 46: 70-6.
- Eisen DB, Asgari MM, Bennett DD, Connolly SM, Dellavalle RP, Freeman EE, et al. Guidelines of care for the management of actinic keratosis. *J Am Acad Dermatol* 2021 Oct; 85(4): 209-33.
- Figueras Nart I, Cerio R, Dirschka T, Dréno B, Lear JT, Pellacani G, et al. Defining the actinic keratosis field: a literature review and discussion. *J Eur Acad Dermatol Venereol* 2018 Apr; 32(4): 544-63.
- Willenbrink TJ, Ruiz ES, Cornejo CM, Schmults CD, Arron ST, Jambusaria-Pahlajani A. Field cancerization: Definition, epidemiology, risk factors, and outcomes. *J Am Acad Dermatol* 2020 Sep; 83(3): 709-17.
- Neagu N, Dianzani C, Venuti A, Bonin S, Voidăzan S, Zalaudek I, et al. The role of HPV in keratinocyte skin cancer development: A systematic review. *J Eur Acad Dermatol Venereol* 2023 Jan; 37(1): 40-6.
- Marques E, Chen TM. Actinic Keratosis. [Updated 2022 May 9]. In: StatPearls [Internet]. Treasure Island (FL): Stat-



- Pearls Publishing; 2022 Jan. Available from: <https://www.ncbi.nlm.nih.gov/books/NBK557401/>
16. Cramer P, Stockfleth E. Actinic keratosis: where do we stand and where is the future going to take us? *Expert Opin Emerg Drugs* 2020 Mar; 25(1): 49-58.
  17. Nashan D, Meiss F, Müller M. Therapeutic strategies for actinic keratoses—a systematic review. *Eur J Dermatol EJD* 2013 Feb; 23(1): 14–32.
  18. Noels EC, Hollestein LM, van Egmond S, Lugtenberg M, van Nistelrooij LPJ, Bindels PJE, et al. Healthcare utilization and management of actinic keratosis in primary and secondary care: a complementary database analysis. *Br J Dermatol* 2019 Sep; 181(3): 544-53.
  19. Arisi M, Guasco Pisani E, Calzavara-Pinton P, Zane C. Cryotherapy for Actinic Keratosis: Basic Principles and Literature Review. *Clin Cosmet Investig Dermatol* 2022 Mar 5 ;15: 357-65.
  20. Dianzani C, Conforti C, Giuffrida R, Corneli P, di Meo N, Farinazzo E, et al. Current therapies for actinic keratosis. *Int J Dermatol* 2020 Jun; 59(6): 677–84.
  21. Berman B, Shabbir AQ, MacNeil T, Knudsen KM. Variables in Cryosurgery Technique Associated With Clearance of Actinic Keratosis. *Dermatol Surg* 2017 Mar; 43(3): 424-30.
  22. Zane C, Facchinetti E, Rossi MT, Specchia C, Ortel B, Calzavara-Pinton P. Cryotherapy is preferable to ablative CO<sub>2</sub> laser for the treatment of isolated actinic keratoses of the face and scalp: a randomized clinical trial. *Br J Dermatol* 2014 May; 170(5): 1114-21.
  23. Heppt MV, Steeb T, Ruzicka T, Berking C. Cryosurgery combined with topical interventions for actinic keratosis: a systematic review and meta-analysis. *Br J Dermatol* 2019 Apr; 180(4): 740-8.
  24. Agarwal K, Podder I, Cockerell CJ, Kassir M, Grabbe S, Goldust M et al. Update on diagnosis and treatment of actinic keratosis. *Dermatological Reviews* 2022; 1-10.
  25. de Vries K, Prens EP. Laser treatment and its implications for photodamaged skin and actinic keratosis. *Curr Probl Dermatol* 2015; 46: 129-35.
  26. Gupta AK, Paquet M. Network meta-analysis of the outcome “participant complete clearance” in nonimmunosuppressed participants of eight interventions for actinic keratosis: a follow-up on a Cochrane review. *Br J Dermatol* 2013 Aug; 169(2): 250–9.
  27. Jansen MHE, Kessels JPHM, Nelemans PJ, Kouloubis N, Arits AHMM, van Pelt HPA, et al. Randomized Trial of Four Treatment Approaches for Actinic Keratosis. *N Engl J Med* 2019 Mar 7; 380(10): 935–46.
  28. Rosenberg AR, Tabacchi M, Ngo KH, Wallendorf M, Rosman IS, Cornelius LA, et al. Skin cancer precursor immunotherapy for squamous cell carcinoma prevention. *JCI Insight* 2019 Mar 21; 4(6): e125476.
  29. Garofalo V, Geraci F, Di Prete M, Lanna C, Lozzi F, Cosio T, et al. Early clinical response to 5-fluorouracil 0.5% and salicylic acid 10% topical solution in the treatment of actinic keratoses of the head: an observational study. *J Dermatolog Treat* 2022 Aug; 33(5): 2664-9.
  30. de Oliveira ECV, da Motta VRV, Pantoja PC, Ilha CSO, Magalhães RF, Galadari H, et al. Actinic keratosis - review for clinical practice. *Int J Dermatol* 2019 Apr; 58(4): 400-7.
  31. Kopera, D. Earliest stage treatment of actinic keratosis with imiquimod 3.75% cream: Two case reports—Perspective for non melanoma skin cancer prevention. *Dermatologic Therapy* 2020; 33: e13517.
  32. Farr MA, Joshi TP, Lewis DJ. Resiquimod: a new topical immune-response modifier for the treatment of actinic keratosis. *Expert Opin Emerg Drugs* 2021 Dec; 26(4): 433-4.
  33. Hashim PW, Chen T, Rigel D, Bhatia N, Kircik LH. Actinic Keratosis: Current Therapies and Insights Into New Treatments. *J Drugs Dermatol* 2019 May 1; 18(5): 161-6.
  34. Kostovic K, Gulin SJ, Mokos ZB, Ceovic R. Topical Ingenol Mebutate: A New Treatment Modality for Multiple Actinic Keratoses and Field Cancerization. *Anticancer Agents Med Chem* 2017; 17(10): 1304-11.
  35. Bobyr I, Campanati A, Consales V, Martina E, Molinelli E, Diotallevi F, Brisigotti V, Giangiacomi M, Ganzetti G, Giuliadori K, Offidani A. Ingenol mebutate in actinic keratosis: a clinical, videodermoscopic and immunohistochemical study. *J Eur Acad Dermatol Venereol.* 2017 Feb;31(2):260-266. doi: 10.1111/jdv.13831. Epub 2016 Jul 25. PMID: 27453064.
  36. Risk of squamous cell carcinoma on skin areas treated with ingenol mebutate gel, 0.015% and imiquimod cream, 5%. ClinicalTrials.gov identifier: NCT01926496. Updated August 21, 2020. Accessed February 1, 2023. <https://clinicaltrials.gov/ct2/show/NCT01926496>.
  37. Schlesinger T, Stockfleth E, Grada A, Berman B. Tirbanibulin for Actinic Keratosis: Insights into the Mechanism of Action. *Clin Cosmet Investig Dermatol* 2022 Nov 16; 15: 2495-506.
  38. Dao DD, Sahni VN, Sahni DR, Balogh EA, Grada A, Feldman SR. 1% Tirbanibulin Ointment for the Treatment of Actinic Keratoses. *Ann Pharmacother* 2022 Apr; 56(4): 494-500.
  39. Heppt MV, Dykukha I, Graziadio S, Salido-Vallejo R, Chapman-Rounds M, Edwards M. Comparative Efficacy and Safety of Tirbanibulin for Actinic Keratosis of the Face and Scalp in Europe: A Systematic Review and Network Meta-Analysis of Randomized Controlled Trials. *J Clin Med* 2022 Mar 16; 11(6): 1654.
  40. Mpourazanis G, Korschake W, Vogiatzis R, Papalexis P, Georgakopoulou VE, Ntritsos G, et al. The Role and Effectiveness of Photodynamic Therapy on Patients With Actinic Keratosis: A Systematic Review and Meta-Analysis. *Cureus* 2022 Jun 28; 14(6): e 26390.

41. Frommeyer TC, Rohan CA, Spandau DE, Kemp MG, Wan-ner MA, Tanzi E, et al. Wounding Therapies for Prevention of Photocarcinogenesis. *Front Oncol* 2022 Jan; 11: 131-2.
42. Sidiropoulou P, Gregoriou S, Rigopoulos D, Kontochristo-poulos G. Chemical Peels in Skin Cancer: A Review. *J Clin Aesthetic Dermatol* 2020 Feb; 13(2): 53-7.
43. Soleymani T, Lanoue J, Rahman Z. A Practical Approach to Chemical Peels: A Review of Fundamentals and Step-by-step Algorithmic Protocol for Treatment. *J Clin Aesthet Der-matol*. 2018 Aug;11(8):21-28. Epub 2018 Aug 1. PMID: 30214663; PMCID: PMC6122508.
44. Melo CB de, Costa ALF da, Santos MM de S, Marcos G de CP. Comparison between 5% imiquimod cream and Jess-ner's solution with 35% trichloroacetic acid chemical peel in the treatment of the facial field cancerization. *Surg Cosmet Dermatol*. 2019;11(4):299-304.
45. Wambier C, Lee K, Soon S, Sterling J, Rullan P, Brody H, et al. Comments on sequential Jessner's + 35% TCA peel for the treatment of facial field cancerization. *Surg Cosmet Dermatol*. 2020 Mar; 12: 87-9.
46. Tai F, Shah M, Pon K, Alavi A. Laser Resurfacing Mono-therapy for the Treatment of Actinic Keratosis. *J Cutan Med Surg* 2021 Nov-Dec; 25(6): 634-42.
47. Yu N, Luo X, Wei T, Zhang Q, Yu J, Wu L, Su J, Chen M, Huang K, Li F, Xie Y, Fang F, Zhang L, He R, Chen X, Zhao S, Bu W. Dermabrasion combined with photodynamic therapy: a new option for the treatment of non-melanoma skin cancer. *Lasers Med Sci*. 2022 Mar;37(2):1255-1263. doi: 10.1007/s10103-021-03381-3. Epub 2021 Aug 8. PMID: 34365550.
48. Weinstock MA, Thwin SS, Siegel JA, Marcolivio K, Means AD, Leader NF, et al. Chemoprevention of Basal and Squa-mous Cell Carcinoma With a Single Course of Fluorouracil, 5%, Cream: A Randomized Clinical Trial. *JAMA Dermatol* 2018 Feb 1; 154(2): 167-74.
49. Chen AC, Martin AJ, Choy B, Fernández-Peñas P, Dalziell RA, McKenzie CA, et al. A Phase 3 Randomized Trial of Nicotinamide for Skin-Cancer Chemoprevention. *N Engl J Med* 2015 Oct 22; 373(17): 1618-26.
50. Sinclair R, Baker C, Spelman L, Supranowicz M, MacMa-hon B. A review of actinic keratosis, skin field cancerisation and the efficacy of topical therapies. *Australas J Dermatol* 2021 May; 62(2): 119-23.