

# The common dementias in elderly population: Limbic Age-Related TDP-43 Encephalopathy and Primary Age-Related Tauopathy

Nenad Bogdanović, MD, PhD, Senior Consultant, Professor, Theme Aging<sup>1</sup>

<sup>1</sup> Karolinska University Hospital and Karolinska Institute, Stockholm, Sweden

## OPEN ACCESS

### Correspondence:

Nenad Bogdanović  
nenad.bogdanovic@ki.se

This article was submitted to RAD  
CASA - Medical Sciences  
as the original article

### Conflict of Interest Statement:

The authors declare that the research was conducted in the absence of any commercial or financial relationships that could be construed as a potential conflict of interest.

**Received:** 30 May 2024

**Accepted:** 3 June 2024

**Published:** 25 June 2024

### Citation:

Bogdanović N. The common dementias in elderly population: Limbic Age-Related TDP-43 Encephalopathy and Primary Age-Related Tauopathy 563=66-67 (2024): 58-64  
DOI: 10.21857/9xn31cw6vy

Copyright (C) 2024 Bogdanović N. This is an open-access article distributed under the terms of the Creative Commons Attribution License (CC BY). The use, distribution or reproduction in other forums is permitted, provided the original author(s) and the copyright owner(s) are credited and that the original publication in this journal is cited, in accordance with accepted academic practice. No use, distribution or reproduction is permitted which does not comply with these terms.

## ABSTRACT:

Alzheimer's disease (AD) is the main cause of dementia and accounts for 60% of dementia syndromes in people older than 75 years. Alzheimer-like clinical picture is often assumed to be the underlying cause of dementia in elderly patients. The correct classification of AD and non-AD is mandatory to study disease mechanisms or new treatment possibilities. A typical clinical picture for AD consists of a progressive cognitive impairment, brain imaging that is in line with AD, and CSF biomarkers and APOE genotype supporting the diagnosis of AD. Use of biomarkers have carried out individuals with mild cognitive impairment who are amyloid-negative addressing a conceptually separate clinical entity named suspected non-Alzheimer disease pathophysiology (SNAP). SNAP clinical progression can mimic AD that makes final diagnose and treatment up to 30% uncertain in the clinical centers that are not using biomarkers. The neurobiological bases non-AD pathologies are common with advancing age in impaired and clinically normal elderly people. These limbic pathologies include argyrophilic grain disease, Tangle predominant dementia, TDP-43 proteinopathy with the prevalence of dementia up to 20%. The terms Primary age-related tauopathy (PART) and Limbic-dominant TDP-43 age-related encephalopathy (LATE) have been proposed as a most common and useful practical clinical construct to describe this phenomenon in >80 years old individuals. Thus, it is highly important to establish the correct timely diagnosis and to start an adequate/personalized therapeutic intervention.

**KEYWORDS:** SNAP, LATE, PART, atypical Alzheimer, dementia, elderly

## SAŽETAK:

UOBIČAJENE DEMENCIJE U STARIJOJ POPULACIJI: LIMBIČKA TDP-43 ENCEFALOPATIJA POVEZANA SA STARENJEM I PRIMARNA TAUOPATIJA POVEZANA SA STARENJEM

Alzheimerova bolest (AD) glavni je uzrok demencije i čini 60% sindroma demencije kod osoba starijih od 75 godina. Često se pretpostavlja da je klinička slika slična Alzheimerovoj temeljni uzrok demencije u starijih bolesnika. Ispravna klasifikacija AD i ne-AD obavezna je za proučavanje mehanizama bolesti ili novih mogućnosti liječenja. Tipična klinička slika za AD sastoji se od progresivnog kognitivnog oštećenja, slikovne slike mozga koja je u skladu s AD-om, biomarkera likvora i genotipa APOE koji podržavaju dijagnozu AD-a. Upotreba biomarkera provedena je kod pojedinaca s blagim kognitivnim oštećenjem koji su negativni na amiloid adresirajući konceptualno odvojeni klinički entitet nazvan patofiziologija suspektne ne-Alzheimerove bolesti (SNAP). Klinička progresija SNAP-a može oponašati AD što čini konačnu dijagnozu i liječenje do 30% nesigurnima u kliničkim centrima koji ne koriste biomarkere. Neurobiološke osnove ne-AD patologija česte su s odmakom u dobi kod oštećenih i klinički normalnih starijih osoba. Ove limbičke patologije uključuju argyrophilic grain disease, Tangle

predominantnu demenciju, TDP-43 proteinopatiju s prevalencijom demencije do 20%. Pojmovi primarna tauopatija povezana sa starenjem (PART) i limbička dominantna TDP-43 encefalopatija povezana sa starenjem (LATE) predloženi su kao najčešći i najkorisniji praktični klinički konstrukt za opisivanje ovog fenomena kod osoba starijih od 80 godina. Stoga je vrlo važno pravovremeno postaviti ispravnu dijagnozu i započeti adekvatnu/personaliziranu terapijsku intervenciju.

**KLJUČNE RIJEČI:** SNAP, KASNO, DIO, atipični Alzheimer, demencija, starije osobe

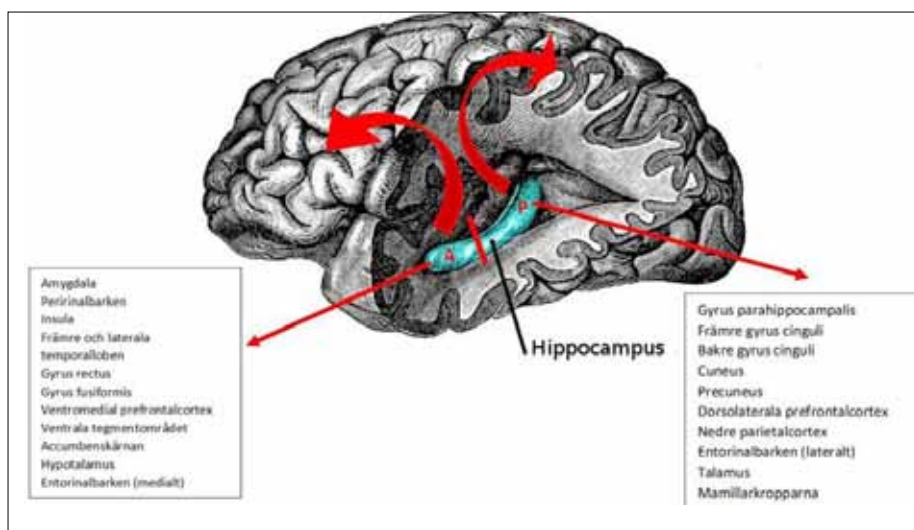
### THE COMMON DEMENTIAS IN ELDERLY POPULATION: LIMBIC AGE-RELATED TDP-43 ENCEPHALOPATHY AND PRIMARY AGE-RELATED TAUOPATHY

The most common cause of amnesic dementia in the elderly is Alzheimer's disease (AD) and evidence of AD-related neuropathological changes, amyloid plaques and tangles are confirmed by neuropathology (ADNC). Everyday clinical practice proves that elderly patients can have cognitive impairment and dementia without having amyloid deposits in the brain.

For practical reasons, this patient group is called SNAP (suspected non-Alzheimer disease pathophysiology), which is a construct introduced by Clifford Jack in 2014 when operational NIA-AA criteria for preclinical Alzheimer's disease were formulated. This term should be avoided in clinical routine. Many years ago, neuropathological analysis showed that with increased life expectancy, cognitive impairment/dementia can be characterized by the presence of limbic-dominant TDP-43 age-related encephalopathy neuropathological confirmed (LATE-NC) or by primary age-related tauopathy neuropathological confirmed (PART-NC) which, so far, can only be confirmed by autopsy. However, the prevalence and coexistence of these brain pathologies with high morbidity and clinical features is still uncertain.

The common pathoanatomical changes for these amnesic types of dementia are involvement of limbic structures at the onset of

the disease. The role of the hippocampus, thalamic nuclei and mamillary bodies etc. in providing the necessary neural substrate for acquiring and retaining new information is well known. It is unlikely that these structures themselves contain specific memories, but somehow, they provide a means to store and retrieve memories, especially those that are being consolidated. The most extensively studied of these limbic regions is the hippocampus, which has been studied since 1956 in the famous case of H.M., a patient who showed severe anterograde amnesia after bilateral amygdalo-hippocampectomy for seizure control (1). To understand the morpho-clinical characteristics of LATE-NC and PART-NC, we need to reflect upon the entorhinal cortex/hippocampal anatomy (2). The human hippocampus has anatomically distinct anterior and posterior segments associated with different functional specialization, morphology, and connectivity patterns. Thus, accumulation of neuropathology in different PART-NCs of the hippocampus can produce different clinical pictures. LATE-NC and PART-NC neuropathology is characterized by accumulation in the predominantly anterior PART-NC of the hippocampus, amygdala and entorhinal cortex, indicating dysfunction in the anterior hippocampal projection areas (Figure 1). In the terminal stages, the neuropathology spreads throughout the hippocampus towards the rest of the limbic areas.



*Figure 1. Connections of the anterior (A) and posterior (P) hippocampus in humans (for details see Poppenk 2013). Two red arrows indicate the projection pattern of the anterior and posterior hippocampus, respectively.*

## LATE-NC

LATE-NC is neuropathologically characterized by accumulations of transactive DNA-binding protein 43 kDa (TDP-43), a prevalent neuropathology in old age (3). This condition has been detected in over 20% of brains in community autopsy series and PART-NC is particularly common (30%–50%) in people over 80 years of age (4). TDP43 pathology was discovered in 2006 as a primary pathological feature of frontotemporal lobar degeneration with TDP-43 inclusions (FTLD-TDP), amyotrophic lateral sclerosis and later in hippocampal sclerosis and amnesic cognitive impairment not associated with FTLD/ALS (5). Additionally, TDP-43 pathology is now considered to occur in many other conditions (6). Although diagnostic ambiguities still exist in TDP-43 neuropathological assessments, LATE-NC has distinctive features including the neuroanatomical distribution of TDP-43 pathology, clinical features, genetic risk factors and epidemiology (7,8).

## LATE-NC vs ADNC

LATE-NC is strongly associated with amnesic dementia, independent of other known brain pathologies. ADNC and LATE-NC are genetically pleiotropic: Apolipoprotein E  $\epsilon 4$  is also associated with increased risk of LATE-NC as in ADNC. TDP-43 pathology may co-localize with tau neurofibrillary tangles. ADNC and LATE-NC pathological changes are independent of each other, but up to 80% of individuals with LATE-NC may have co-morbid ADNC. Many elderly patients with severe

ADNC do not inevitably lead to LATE-NC. It has been suggested that TDP-43 proteinopathy in the context of ADNC is merely an “added” pathology, analogous to Lewy body pathology in the amygdala (9). However, the presence of LATE-NC in cases with concomitant ADNC is still very important to note, as ADNC with LATE-NC has a more severe clinical phenotype than ADNC without LATE-NC (10; 11). The clinical symptomatology is strongly modified by the extent of ADNC, and possibly with other concomitant pathologies such as hippocampal sclerosis and arteriolosclerosis, associated with LATE-NC. Recent imaging studies also suggest that brains with ADNC and co-morbid LATE-NC have more atrophic hippocampi than those with ADNC alone (3,12-15).

Clinically, patients with ADNC who have co-morbid LATE-NC are on average older (>80 years) had higher ADNC burden and had poorer cognitive performance and a tendency to manifest behavioural and neuropsychiatric symptoms than those with ADNC without LATE-NC. The presence of “mixed” pathologies is important because the clinical manifestations vary with different combinations of pathologies. For example, “pure LATE-NC” is, on average, associated with a less severe clinical phenotype than “pure ADNC”. Important to emphasize that the effect of LATE-NC is limited to reduced, especially episodic memory that is specifically related to the anatomy and the connectivity of the anterior hippocampus (16). The combination (ADNC + LATE-NC) is associated with a more aggressive clinical course (Table 1).

	LATE-NC	ADNC	LATE-NC och ADNC
Protein	TDP-43	$\beta$ -amyloid, tau	TDP-43, $\beta$ -amyloid, tau
Prevalence, cognitive Impairment/dementia	cca 20 %	cca 40 %	25-60 % of AD patients
Genetic risk	TMEM106B, RBFOX1, APOE, GRN	APOE, TREM2, CLU, B1N1	As in LATE-NC or AD
Clinical features	slow progression of memory impairment possible behavioral changes	Amnesic and multidomain cognitive impairment	Severe cognitive impairment/dementia Rapid functional decline
Anatomy of neurodegeneration	Hippocampus and amygdala Top of the temporal lobe Medial frontal area Orbital cortex	Hippocampus, amygdala Inferior temporal lobe Lateral parietal lobe Precuneus, posterior cingular cortex cingular g	As in LATE-NC and AD
IMaging biomarkers	MRI, F <sup>18</sup> PET-FDG (bild 3)	MRT, F <sup>18</sup> PET-FDG, -amyloid, - tau	MRT, F <sup>18</sup> PET-FDG, -amyloid, - tau

Table 1.

### LATE-NC vs FTLD-TDP

An important question is whether FTLD-TDP and LATE-NC cases could be distinguished from each other. The clinical and pathological boundaries between LATE-NC and FTLD-TDP have not been fully delineated, (3). LATE-NC histopathology is like that seen in FTLD-TDP type A (17). Arguments for similarities between LATE-NC and FTLD-TDP include neuroimaging detection of frontal and temporal atrophy in those cases with autopsy-proven LATE-NC, less dramatic atrophy overall than FTLD-TDP cases, but still in the same (3,18) or not completely identical anatomical areas (6). The main differences between FTLD-TDP and LATE-NC are in epidemiology and clinical presentation. LATE-NC is much more common and affects older individuals, with heterogeneous clinical features (3).

### PART-NC

Even before the term “primary age-related tauopathy (PART-NC)” was proposed in 2014, pathologists had observed localized neurofibrillary degeneration in the brains of aged subjects with relatively well-preserved cognitive function that was mostly confined to medial temporal regions. These findings were somewhat informally described as “aging changes” because the characteristics were considered insufficient for a diagnosis of Alzheimer’s disease. The newly proposed consensus term (ie, PART-NC) includes features ranging from the presence of isolated neurofibrillary tangles in cognitively normal aged brains to tangle-predominant senile dementia (TPSD) and argyrophilic grain disease (AGD) (19,20).

In the common clinical picture, there is profound cognitive impairment that interferes with daily activities in some affected individuals within this population. Thus, the consensus term PART-NC was proposed by researchers of neurodegenerative diseases as a more objective and quantitative description of pathological disease status separate from the clinical presentation. The term PART-NC is inspired by the pathological classification system for AD of the National Institute on Aging-Alzheimer’s Association (21). Since their introduction, the clinicopathological features of PART-NC have been elucidated more precisely (19, 22-25).

The gross features of a brain with PART-NC may include graded atrophy primarily located in the medial temporal lobe; often dominant in the left hippocampus (23) with very mild diffuse neocortical atrophy that may occur in some cases but without or very few amyloid plaques (26). In TPSD, AD-type NFTs, including ghost tangles, are mainly distributed in the hippocampus and medial temporal lobe and correspond to Braak stages I–III in the majority of patients and to stage IV in rare cases (27). NFTs can also be observed in subcortical structures, such as the amygdala, nucleus basalis of Meynert, nucleus accumbens, hypothalamus, thalamus, and the olfactory system (bulb and cortex), and in the brainstem, including the substantia nigra, locus coeruleus, dorsal raphe nucleus, and medulla oblongata, where NFTs develop at a younger age, sometimes even in teenagers (27).

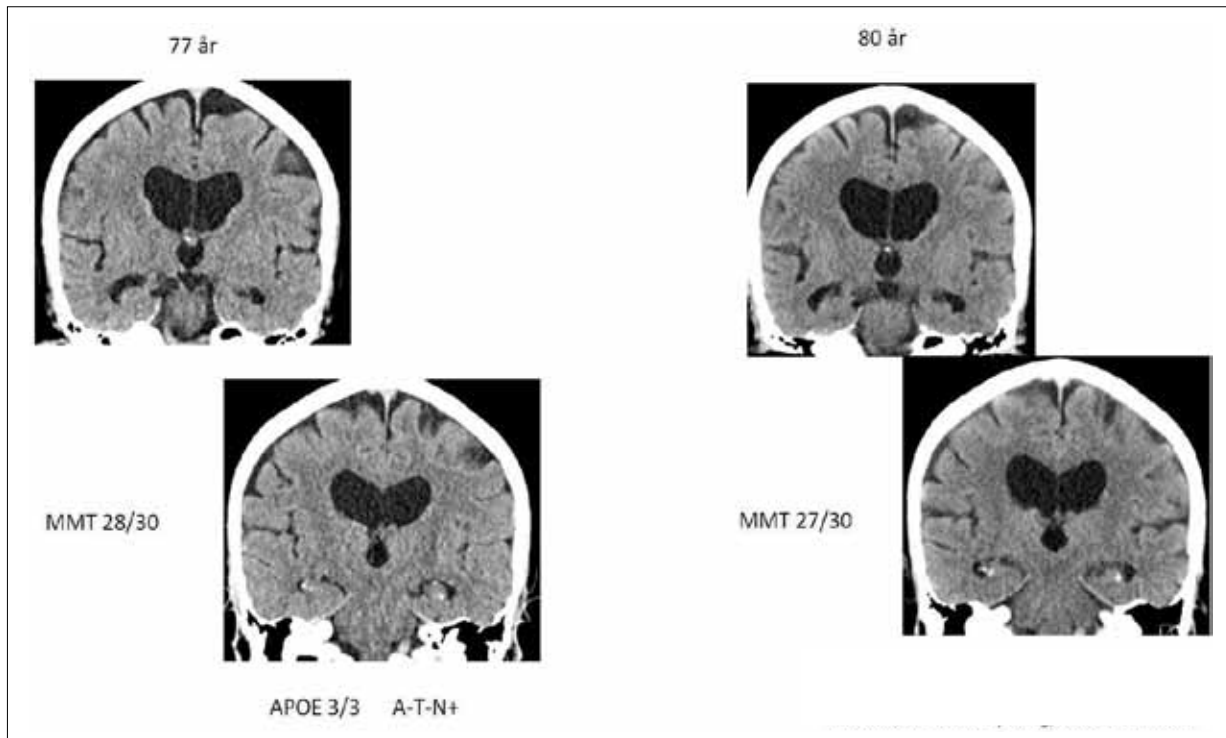
uleus, dorsal raphe nucleus, and medulla oblongata, where NFTs develop at a younger age, sometimes even in teenagers (27).

### Is PART-NC A PART-NC OF THE AD CONTINUUM?

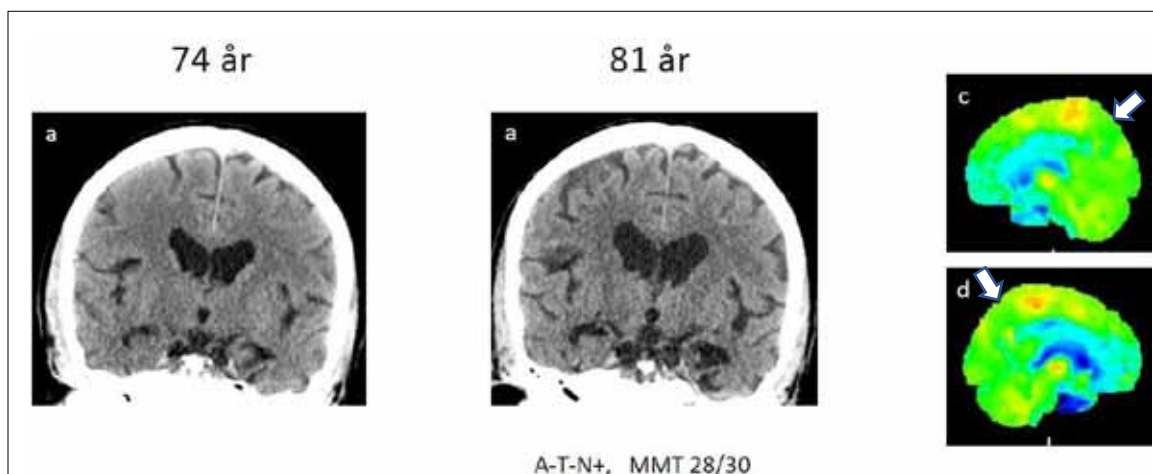
Considering PART-NC as being on the AD continuum, particularly comparison with limbic-dominant form of AD, has been discouraged for several reasons (13, 26). First, PART-NC is associated with lower Braak NFT stages and fewer, or an absence of, A $\beta$  plaques. Second, patients with PART-NC have a higher age of onset, longer disease duration and less severe cognitive impairment. Third, the frequency of APOE  $\epsilon$ 4 is much lower in PART-NC than in the normal elderly population, (28). In the absence of A $\beta$ , as seen in definite PART-NC, tau-positive NFTs or argyrophilic grains tend to be more abundant with older age at death (13). The implications of the association of PART-NC with diffuse amyloid and neuritic plaques also remain to be elucidated, although a quantitative threshold for A $\beta$  deposition, up to Thal phase 2, has been suggested (19). However, the functional interaction between tau and A $\beta$ , as well as the relationship between PART-NC and AD, remains to be elucidated (20, 29). It has been suggested that a neuropathological diagnosis of PART-NC should be applied conservatively to cases where NFT or argyrophilic grains primarily affects the hippocampus/limbic area, and where there is a lack of A $\beta$  deposits and no evidence of any other dementia characterized by NFT (30). Finally, to understand the clinicopathological entity of PART-NC, mandatory neuropathological analysis is needed to establish which will provide a solid foundation for a more in-depth understanding of age-related neurodegenerative changes.

### PART-NC- CLINICAL FEATURE

In a longitudinal analysis, increasing accumulation of neurofibrillary tangles or argyrophilic grains in PART-NC is associated with faster cognitive decline. (31). Comparison of longitudinal changes of cognitive performance in 5 domains (memory, attention, executive function, language and visuospatial ability) and in the Mini-Mental State Examination (MMSE) has shown a highly significant difference between patients with PART-NC and AD. In all these domains showed AD subjects a faster rate of decline than PART-NC subjects (32). Brain imaging with MRI can visualize the differences in anatomy of the atrophic regions in patients with PART-NC and AD. Atrophic changes in the anterior hippocampus are greater than in the posterior PART-NC. Precuneus and parietal cortex are pathognomonic for AD disease but not for PART-NC which makes a clear distinction in clinical practice (Figure 2). Hypometabolic pattern in the brain is also characteristic of PART-NC (Figure 3).



**Figure 2.** Computed tomography of the brain in 80-year-old patient with amnesic cognitive impairment accompanied by behavioral symptoms. Cognitive function has been slowly deteriorating over several years. Neuropsychological examination has revealed the cognitive impairment (amnesic with executive impairments) in more detail than screening MMT tests. In the last three years, atrophy accelerated in the anterior hippocampus (upper row), L>R, compared to cortical parts. The second row shows non-atrophied posterior hippocampus. The patient did not have amyloid or tau pathology in the CSF. APOE allele 2/3. The clinical picture and limbic atrophy of lesser degree correspond to PART. For the final diagnosis, neuropathological analysis is mandatory.



**Figure 3.** Computerized tomography (a,b) and PET-FDG (c,d) of 81-year-old patient with amnesic cognitive impairment without AD biomarkers in CSF and with APOE alleles 3/3. Cognitive decline lasted more than seven years and the atrophy accelerated mostly in the limbic areas of the hippocampus V>H with atrophy of the amygdala which contrasts with otherwise essentially preserved cortex. PET-FDG shows hypometabolism in the limbic area of the hippocampus, cingulate and medial frontal regions. Both precuneus areas (white arrows) have normal metabolism. The clinical picture with marked limbic atrophy is similar to LATE-NC but neuropathological examination is mandatory for the final diagnosis.

PART-NC brains lack the APOE  $\epsilon 4$  allele, which is strongly associated with the risk of AD. The frequency of APOE  $\epsilon 4$  in PART-NC is approximately 10%, while its prevalence in AD exceeds 45%. A major genetic risk factor for PART-NC is the microtubule-associated protein tau (MAPT) gene. H1 haplotype, is risk factor for subtype of PART-NC, AGD and is also an accepted risk factor for progressive supranuclear palsy (PSP), corticobasal degeneration (CBD). Patients with PART-NC pathology have mild cognitive impairment (20). Greater failure has been noted as another subtype of PART-NC, so-called TPSD, where the initial symptoms usually include memory disturbances (30). During disease progression, a relatively well-preserved personality is seen. Mental disturbances, such as disorientation, depression and paranoid thinking have also been observed (30, 33). PART-NC represents a subtype of atypical AD that has a later onset of symptoms with a slower disease progression. Further distinction of PART-NC from AD as a distinct disease entity will rely on prospective biomarker and PET imaging studies. Further

work is also needed to identify a distinct biological mechanism separate from AD. A biochemical distinction between PART-NC and AD-associated NFT has not yet been achieved.

In conclusion, advances in dementia diagnostics suggesting that we have clinically identified and unlocked the well-known neopathological conditions triggering cognitive decline and dementia in the elderly caused by PART-NC or LATE. It has been shown that we remain at the limit of detection and that our clinical diagnostic repertoire is still inadequate. Understanding such diagnostic ambiguities is important to assign appropriate diagnoses, avoid frequent mistaken diagnose with AD and select competent therapeutic management strategies for patients with mild cognitive impairment and dementia in advanced age. At present, communication between clinicians, neuropathologists and researchers needs acronyms LATE-NC and PART-NC before pathological, biochemical processes and clinical picture are fully defined.

## REFERENCES:

- Scoville WB, Milner B: Loss of recent memory after bilateral hippocampal lesions. *J Neurol Neurosurg Psychiatry* 1957; 20:11-21
- Hyman BT, Van Hoesen GW, Kromer LJ, et al: Perforant pathway changes and the memory impairment of Alzheimer's disease. *Ann Neurol* 1986; 20:472-481
- Nelson PT, Dickson DW, Trojanowski JQ, et al. Limbic-predominant age-related TDP-43 encephalopathy (LATE): Consensus working group report. *Brain* 2019;142:1503-27
- Nelson PT, Brayne C, Flanagan ME, et al. Frequency of LATE neuropathologic
- change across the spectrum of Alzheimer's disease neuropathology: Combined data from 13 community-based or population-based autopsy cohorts. *Acta Neuropathol* 2022;144:27-44
- Amador-Ortiz C, Lin W-L, Ahmed Z, et al. TDP-43 immunoreactivity in hippocampal sclerosis and Alzheimer's disease. *Ann Neurol*. 2007;61(5):435-45
- Chornenkyy Y, Fardo DW, Nelson PT. Tau and TDP-43 proteinopathies: kindred pathologic cascades and genetic pleiotropy. *Lab Invest*, 2019, 99:993-1007.
- Coyle-Gilchrist IT, Dick KM, Patterson K, Vazquez Rodriguez P, Wehmann E, Wilcox A et al Prevalence, characteristics, and survival of frontotemporal lobar degeneration syndromes. 2016: *Neurology* 86:1736-1743.
- Crary JF, Trojanowski JQ, Schneider JA, et al. Primary age-related tauopathy (PART-NC): a common pathology associated with human aging. *Acta Neuropathol* 2014; 128: 755-66.
- Josephs KA, Mackenzie I, Frosch MP, Bigio EH, Neumann M, Arai T, et al. LATE to the PART-NC-y. *Brain* 2019; 142: e47.
- Nelson PT, Abner EL, Schmitt FA, Kryscio RJ, Jicha GA, Smith CD, et al. Modeling the association between 43 different clinical and pathological variables and the severity of cognitive impairment in a large autopsy cohort of elderly persons. *Brain Pathol* 2010; 20: 66-79
- Robinson JL, Geser F, Stieber A, Umoh M, Kwong LK, Van Deerlin VM, et al. TDP-43 skeins show properties of amyloid in a subset of ALS cases. *Acta Neuropathol* 2013; 125: 121-31.
- Dawe RJ, Bennett DA, Schneider JA, Arfanakis K. Neuropathologic correlates of hippocampal atrophy in the elderly: a clinical, pathologic, postmortem MRI study. *PLoS One*, 2011; 6: e26286
- Josephs KA, Dickson DW, Tosakulwong N, Weigand SD, Murray ME, Petrucelli L, et al. Rates of hippocampal atrophy and presence of post-mortem TDP-43 in patients with Alzheimer's disease: a longitudinal retrospective study. *Lancet Neurol* 2017a; 16:917-24
- Sahoo A, Bejanin A, Murray ME, Tosakulwong N, Weigand SD, Serie AM, et al. TDP-43 and Alzheimer's disease pathologic subtype in non-amnesic Alzheimer's disease dementia. *J Alzheimers Dis* 2018; 64: 1227-33.
- Bejanin A, Murray ME, Martin P, Botha H, Tosakulwong N, Schwarz CG, et al. Antemortem volume loss mirrors TDP-43 staging in older adults with non-frontotemporal lobar degeneration. *Brain* 2019; 142: 3621-35.

17. Wilson RS, Yang J, Yu L, et al. Postmortem neurodegenerative markers and trajectories of decline in cognitive systems. *Neurology* 2019;92:e831–40
18. Aoki N, Murray ME, Ogaki K, Fujioka S, Rutherford NJ, Rademakers R, et al. Hippocampal sclerosis in Lewy body disease is a TDP-43 proteinopathy similar to FTLD-TDP Type A. *Acta Neuropathol* 2015; 129: 53–64.
19. Kotrotsou A, Schneider JA, Bennett DA, Leurgans SE, Dawe RJ, Boyle PA, et al. Neuropathologic correlates of regional brain volumes in a community cohort of older adults. *Neurobiol Aging* 2015; 36: 2798–805.
20. Crary JF. Primary age-related tauopathy and the amyloid cascade hypothesis: the exception that proves the rule? *J Neurol Neuromedicine* 2016; 1: 53-7.
21. Irwin DJ. Tauopathies as clinicopathological entities. *Parkinsonism Relat Disord* 2016; 22 Suppl 1: S29-33.
22. Hyman BT, Phelps CH, Beach TG, et al. National Institute on Aging- Alzheimer's Association guidelines for the neuropathologic assessment of Alzheimer's disease. *Alzheimers Dement* 2012; 8: 1-13.
23. Bennett RE, DeVos SL, Dujardin S, et al. Enhanced tau aggregation in the presence of amyloid beta. *Am J Pathol* 2017; 187: 1601-12.
24. Josephs KA, Murray ME, Tosakulwong N, et al. Tau aggregation influences cognition and hippocampal atrophy in the absence of beta-amyloid: a clinico-imaging-pathological study of primary age-related tauopathy (PART-NC). *Acta Neuropathol* 2017b; 133: 705-15.
25. Kaufman SK, Del Tredici K, Thomas TL, Braak H, Diamond MI. Tau seeding activity begins in the transentorhinal/entorhinal regions and anticipates phospho-tau pathology in Alzheimer's disease and PART-NC. *Acta Neuropathol* 2018; 136: 57-67
26. Neltner JH, Abner EL, Jicha GA, et al. Brain pathologies in extreme old age. *Neurobiol Aging* 2016; 37: 1-11.
27. Kovacs GG. Invited review: neuropathology of tauopathies: principles and practice. *Neuropathol Appl Neurobiol* 2015; 41: 3-23.
28. Braak H, Thal DR, Ghebremedhin E, Del Tredici K. Stages of the pathologic process in Alzheimer disease: age categories from 1 to 100 years. *J Neuropathol Exp Neurol* 2011; 70: 960–9.
29. Josephs KA, Whitwell JL, Tosakulwong N, et al. TAR DNA-binding protein 43 and pathological subtype of Alzheimer's disease impact clinical features. *Ann Neurol* 2015; 78: 697-709.
30. Duyckaerts C, Braak H, Brion JP, et al. PART-NC is PART-NC of Alzheimer disease. *Acta Neuropathol* 2015; 129: 749-56.
31. Yamada M. Senile dementia of the neurofibrillary tangle type (tangle- only dementia): neuropathological criteria and clinical guidelines for diagnosis. *Neuropathology* 2003; 23: 311-7.
32. Jefferson-George KS, Wolk DA, Lee EB, and McMillan CT. Cognitive Decline Associated with Pathological Burden in Primary Age-Related Tauopathy *Alzheimers Dement*. 2017; 13(9): 1048–1053
33. Bell RW, Yang An, Yusuke Kageyama, Collin English, Gay L. Rudow, Olga Pletnikova, Madhav Thambisetty, Richard O'Brien, Abhay R. Moghekar, Marilyn S. Albert, Peter V. Rabins, Susan M. Resnick, and Juan C. Troncoso, Neuropathologic, genetic, and longitudinal cognitive profiles in primary age-related tauopathy (PART-NC) and Alzheimer's disease. *Alzheimers Dement*. 2019; 15(1): 8–16.
34. Jellinger KA, Attems J. Neurofibrillary tangle-predominant dementia: comparison with classical Alzheimer disease. *Acta Neuropathol* 2007; 113: 107-17.
35. Braak H, Del Tredici K. The pathological process underlying Alzheimer's disease in individuals under thirty. *Acta Neuropathol* 2011a; 121: 171-81.
36. Braak H, Thal DR, Ghebremedhin E, Del Tredici K. Stages of the pathologic process in Alzheimer disease: age categories from 1 to 100 years. *J Neuropathol Exp Neurol* 2011b; 70: 960-9.
37. Poppenk J, Evensmoen HR, Moscovitch M, Nadel L. Long-axis specialization of the human hippocampus. *Trends Cogn Sci*. 2013, 17(5):230-40
38. Wisse LEM, Nirali Butala, Sandhitsu R. Das, Christos Davatzikos, Bradford C. Dickerson, Sanjeev N. Vaishnavi, Paul A. Yushkevich, David A. Wolk, and the Alzheimer's Disease Neuroimaging Initiative. Suspected non-AD pathology in Mild Cognitive Impairment. *Neurobiol Aging*. 2015 ; 36(12): 3152–3162.

